





# MRI Safety and Devices: An Update and Expert Consensus

Pejman Jabejdar Maralani, MD,<sup>1\*</sup>  Nicola Schieda, MD,<sup>2</sup> Elizabeth M. Hecht, MD,<sup>3</sup>  
Harold Litt, MD, PhD,<sup>4</sup> Nicole Hindman, MD,<sup>5</sup> Chinthaka Heyn, MD, PhD,<sup>1</sup>  
Matthew S. Davenport, MD,<sup>6</sup> Greg Zaharchuk, MD, PhD,<sup>7</sup>   
Christopher P. Hess, MD, PhD,<sup>8</sup> and Jeffrey Weinreb, MD<sup>9</sup>

**CME**

## CME Information: MRI safety and devices: An update and expert consensus

If you wish to receive credit for this activity, please refer to the website: [www.wileyhealthlearning.com/JMRI](http://www.wileyhealthlearning.com/JMRI)

### Educational Objectives

Upon completion of this educational activity, participants will be better able to:  
Address MRI safety concerns of the most commonly encountered implants/devices.

### Activity Disclosures

No commercial support has been accepted related to the development or publication of this activity.

### Faculty Disclosures:

**Editor-in-Chief:** Mark E. Schweitzer, MD, discloses consultant fees from MCRA and MMI.

**CME Editor:** Mustafa R. Bashir, MD, discloses research support from GE Healthcare, Madrigal Pharmaceuticals, NGM Biopharmaceuticals, Siemens Healthcare and Taiwan J Pharma, and consultant fees from RadMD.

### CME Committee:

Bonnie Joe, MD, PhD, discloses author royalties from UpToDate.

Tim Leiner, MD, PhD, discloses research grants from Bayer Healthcare and Philips Healthcare.

Shreyas Vasanawala, MD, PhD, discloses research support from GE Healthcare, and founder's equity in Arterys.

Eric Chang, MD, Feng Feng, MD, and Bruno Madore, PhD; no conflicts of interest or financial relationships relevant to this article were reported.

### Authors:

Harold Litt discloses grant funding from Siemens Healthineers and travel support from GE Healthcare for sponsored research.

Matthew S. Davenport discloses author royalties from UpToDate and Wolters Kluwer.

Greg Zaharchuk discloses research support from GE Healthcare, ownership interest in Subtle Medical, speaker honoraria from Bayer Healthcare.

Jeffrey Weinreb discloses consultant honoraria from Bracco Diagnostics, medicolegal consultant fees from Bayer Healthcare, and consultant fees from CureMetrix.

Pejman Jabejdar Maralani, Nicola Schieda, Elizabeth M. Hecht, Chris Heyn, Nicole Hindman, and Christopher P. Hess reported no conflicts of interest or financial relationships relevant to this article.

This activity underwent peer review in line with the standards of editorial integrity and publication ethics. Conflicts of interest have been identified and resolved in accordance with John Wiley and Sons, Inc.'s Policy on Activity Disclosure and Conflict of Interest.

### Accreditation

John Wiley and Sons, Inc. is accredited by the Accreditation Council for Continuing Medical Education to provide continuing medical education for physicians.

John Wiley and Sons, Inc. designates this journal-based CME activity for a maximum of 1.0 *AMA PRA Category 1 Credit*<sup>™</sup>. Physicians should only claim credit commensurate with the extent of their participation in the activity.

For information on applicability and acceptance of continuing medical education credit for this activity, please consult your professional licensing board.

This activity is designed to be completed within 1 hour. To successfully earn credit, participants must complete the activity during the valid credit period, which is up to two years from initial publication. Additionally, up to 3 attempts and a score of 70% or better is needed to pass the post test.

View this article online at [wileyonlinelibrary.com](http://wileyonlinelibrary.com). DOI: 10.1002/jmri.26909

Received May 17, 2019, Accepted for publication Aug 1, 2019.

\*Address reprint requests to: P.J.M., 2075 Bayview Avenue, Room AG270c, Department of Medical Imaging, University of Toronto, Toronto, Canada.  
E-mail: [pejman.maralani@utoronto.ca](mailto:pejman.maralani@utoronto.ca)

From the <sup>1</sup>Department of Medical Imaging, University of Toronto, Toronto, Canada; <sup>2</sup>Department of Radiology, University of Ottawa, Ottawa, Canada; <sup>3</sup>Department of Radiology, Columbia University, New York, New York, USA; <sup>4</sup>Department of Radiology, University of Pennsylvania, Philadelphia, Pennsylvania, USA; <sup>5</sup>Department of Radiology, New York University, New York, New York, USA; <sup>6</sup>Department of Radiology, University of Michigan, Ann Arbor, Michigan, USA; <sup>7</sup>Department of Radiology, Stanford University, Stanford, California, USA; <sup>8</sup>Department of Radiology and Biomedical Imaging, University of California, San Francisco, California, USA; and <sup>9</sup>Department of Radiology and Biomedical Imaging, Yale University, New Haven, Connecticut, USA

The use of magnetic resonance imaging (MRI) is increasing globally, and MRI safety issues regarding medical devices, which are constantly being developed or upgraded, represent an ongoing challenge for MRI personnel. To assist the MRI community, a panel of 10 radiologists with expertise in MRI safety from nine high-volume academic centers formed, with the objective of providing clarity on some of the MRI safety issues for the 10 most frequently questioned devices. Ten device categories were identified. The panel reviewed the literature, including key MRI safety issues regarding screening and adverse event reports, in addition to the manufacturer's Instructions For Use. Using a Delphi-inspired method, 36 practical recommendations were generated with 100% consensus that can aid the clinical MRI community.

**Level of Evidence:** 5

**Technical Efficacy Stage:** 5

J. MAGN. RESON. IMAGING 2020;51:657–674.

The use of Magnetic Resonance Imaging (MRI) is increasing globally.<sup>1</sup> In addition, medical devices are continually being developed or upgraded, presenting a unique challenge to healthcare professionals who need to ensure compatibility prior to scanning to prevent or reduce potential adverse events (AEs).

Briefly, from an MRI safety perspective, the main concerns stem from: 1) the static magnetic field, which can contribute to projectile effects; 2) the gradient field, which can cause current induction; and 3) the radiofrequency (RF) field, which can result in device heating. All three contribute to specific absorption rate (SAR). Further details are covered by Shellock and Crues.<sup>2</sup> The primary safety concerns in patients with biomedical implants or devices are related to the presence of ferromagnetic materials such as iron or stainless steel. These can potentially move, induce electrical currents, or undergo RF-induced heating.<sup>3</sup> Nonferromagnetic materials such as tantalum, titanium, nitinol, copper, MP35N, or plastic do not pose a risk for movement when exposed to a magnetic field; however, nonferromagnetic metallic objects share the potential to undergo RF-induced heating and current induction, particularly when they are elongated or form a loop.<sup>4</sup>

Concerns regarding the compatibility of MRI and implants led to standardization of medical device testing, labeling, and terminology by ASTM International (including but not limited to F2503, F2052, F2189), while implantable portions of "active"—those that utilize any source of power other than those generated within the human body or gravity—device standards fall under the International Organization for Standardization, Technical Standard (ISO/TS; latest guidelines, ISO/TS 10974:2018). Several guidelines for MRI safety practices have also been issued by radiological societies, eg, the American College of Radiology (ACR),<sup>5</sup> Canadian Association of Radiologists,<sup>6</sup> and European Union.<sup>7</sup> Additional publications<sup>3,8</sup> and online resources, such as [www.MRIsafety.com](http://www.MRIsafety.com), are also available that detail device and MRI compatibility. Despite the abundance of resources, situations outside of those defined by the Instructions For Use (IFUs) still arise, resulting in uncertainty on how to assess safety for an MRI scan and leading to refusal of MRI, which can impact patient care or

treatment decisions. To address some of the more common scenarios that occur, a panel of radiologists reviewed the literature on the MRI safety of 10 frequently questioned categories of devices and used a Delphi-inspired method to generate recommendations on screening and safety procedures. The purpose of this work is to present an updated review outlining the main safety, screening, and scanning concerns, as well as the AE reports for each device category, and to provide the MRI community with practical recommendations. These recommendations are also useful in risk–benefit assessment when patients present in scenarios not detailed in the IFUs.

## METHODS

A group of 10 radiologists, varying in their subspecialty and with 7–35 years of experience, was formed from nine high-volume academic institutions. A modified Delphi approach was chosen, as it facilitates group judgments and allowed for the formation of a multi-institutional panel of experts. The inherent anonymity ensured that all member opinions held equal weighting during the formation of the recommendations. Three Delphi rounds were held with the stop criterion being achievement of 100% consensus on >95% of questions.

An open discussion was first held to determine the 10 medical device categories that would be covered. Based on their subspecialty, one to three radiologists were then assigned to a category and instructed to review and summarize the literature. Product IFUs were also reviewed, as these undergo rigorous scrutiny by the regulating bodies of their respective jurisdiction prior to approval and marketing. For example, in the United States (US), the Food and Drug Administration (FDA) oversees this. Peer-reviewed publications were also included, despite the methodology not necessarily adhering to the standards set by the ASTM International or ISO/TS publications, as they held valuable information regarding the safety concerns of several device categories.

The authors then generated up to eight statements that could be evaluated as recommendations during the Delphi rounds. To ensure consistency among the recommendations, authors were instructed to use MRI safety risk category terminology (Table 1) based on those used by the US FDA.

**TABLE 1. MRI Safety Terminology Used in This Review, Adapted From FDA Definitions<sup>96</sup>**

<b>Terminology</b>	<b>Definition</b>
<b>MR Safe</b>	These items, composed of electrically nonconductive, nonmetallic, and nonmagnetic materials (as per ASTM International guidelines), pose no safety hazards in the MR environment. They may be placed anywhere in the MR environment. Patients with MR Safe devices have no scanning restrictions.
<b>MR Conditional</b>	<p>Items that do not pose known hazards when scanned under the specific conditions provided in the labeling or product manuals. Patients should not be scanned unless the device can be identified and all specific conditions are met. Conditions vary between devices and may differ between internal and external parts of the same device. Conditions and eligibility may also vary by regulatory body.</p> <p>If the device is labeled as MR Conditional, the MRI safety labeling should be matched with the MRI system for:</p> <ul style="list-style-type: none"> <li>• Static field strength</li> <li>• Maximum spatial field gradient</li> <li>• dB/dt limitations (usually only applicable to active implants)</li> <li>• Specific absorption rate (SAR) limits</li> <li>• Anatomic location of isocenter</li> <li>• Scan duration</li> <li>• Any other conditions needed for safe use of the device, for example restrictions on the types of coils that may be used, or device settings</li> </ul> <p>Labels will often include expected temperature increases and artifact extent, which can be used to make an informed risk-benefit decision.</p>
<b>MR Unsafe</b>	These items should not enter the screened patient holding area or scanner room. Patients with implanted MR Unsafe devices in general should not be scanned (see details in text).

In each Delphi round, authors were sent the consolidated sections to review. An electronic questionnaire with the recommendations was subsequently sent out to all authors, with answers limited to either "Agree" or "Disagree." A third-party facilitator collected the results to ensure anonymity, and also reached out to authors for their rationale when their answer differed from the majority. This information was fed back to all authors anonymously and used to provide structure to the teleconference, which occurred in the subsequent week and covered topics where full consensus was not reached. Afterwards, the authors could amend their sections and/or provide improved recommendations. This process was repeated for all statements where full consensus was not reached until the stop criterion was met, after which no teleconference was held.

## RESULTS

Ten categories were chosen for review: 1) epidural and peripheral nerve catheters; 2) spinal cord and peripheral nerve stimulators; 3) cochlear implants; 4) scleral buckles and retinal tacks; 5) coronary and carotid stents; 6) legacy pacemakers and defibrillators; 7) retained epicardial pacer wires and abandoned pacemaker leads; 8) endoscopic hemostatic clips and video capsule endoscopic recording devices; 9) intrauterine

and fallopian tube closure devices; and 10) bullets, shrapnel, and foreign metallic objects.

A total of three Delphi rounds were held, with 100% response rate for each (Fig. 1). In the first Delphi round, 42 recommendations were sent to authors. During the teleconference, three recommendations were removed due to redundancy, and two due to lack of specificity; 100% consensus was achieved on 48.6% (18/37) recommendations. During the second Delphi round, 84.2% (16/19) of the remaining 19 recommendations achieved 100% consensus. On the last Delphi round, 100% (3/3) consensus was achieved. One recommendation was removed during the review process of this article; therefore a total of 36 recommendations with 100% consensus is presented (Table 2).

As most literature regarding clinical MRI safety are limited to 1.5T and 3T, recommendations provided here only apply at these field strengths unless otherwise stated. Although FDA terminology for MRI risk categories (Table 1) were used, it should be noted that recommendations are literature-supported and not jurisdiction-based. Devices with active, implanted components should have the device settings applied as per the IFU whenever possible. However, specific risks and benefits of an MRI scan should always be assessed on a case-by-case basis if an implant does not have MRI labeling or if the MRI conditions indicated in the IFU cannot be followed.

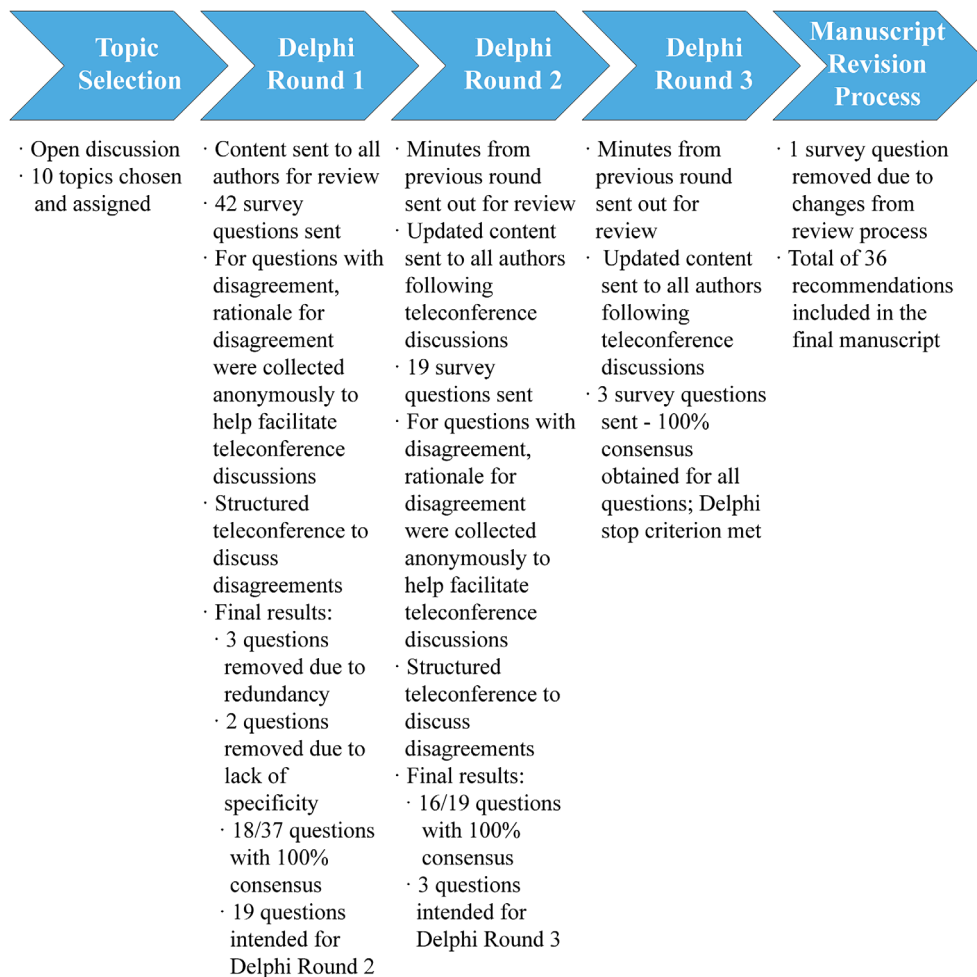


FIGURE 1: Overview of the methodology employed.

## DISCUSSION

### ***Epidural and Peripheral Nerve Catheters (Box 1)***

Epidural and peripheral nerve catheters are placed for continuous delivery of local anesthetics or analgesics into the epidural or perineural space for pain relief. They are often placed for 5–7 days in the postoperative setting for patient-controlled analgesia, although extended periods are common during the palliative care of oncology patients.<sup>9</sup> Peripheral nerve catheters are most commonly used for orthopedic surgeries in the peri- and post- operative period.

Several changes in their material composition and design have occurred over the years.<sup>10</sup> Many of these catheters contain a metal wire that improves their maneuverability and ease of placement. Due to this wire, the specific risks associated with these catheters include potential for displacement when placed in a static magnetic field and RF-induced heating. In 2002, Shellock<sup>11</sup> reported that an epidural catheter manufactured with 604V stainless steel (Arrow International, Walpole, MA) showed limited deflection and rotation at 3T, but communication with Arrow indicates no catheters are currently manufactured using stainless steel. In the only other study found, Owens et al<sup>12</sup> did not adhere to the strict

testing standards published by ASTM International, and ISO/TS 10974 was not published at the time. Instead, the methodology focused on compliance with the FDA's RF and SAR guidelines under *in vitro* settings. They demonstrated the StimuCath Peripheral Nerve (Arrow International) and Perifix FX Epidural (B. Braun Medical, Bethlehem, PA) catheters are MR Unsafe. They also demonstrated that the Epifuse Nylon (Smith/Portex, Dublin, OH), Flex-Tip Plus, and MultiPort Flex-Tip Plus (Arrow International) epidural catheters, and the Contiplex Polyamide (B. Braun Medical) peripheral nerve catheter, do not have RF-heating-related issues and can be left in place at 1.5T. Furthermore, temperature increases by the Contiplex Polayamide (B. Braun Medical) and Epifuse Nylon (Smith/Portex) were limited, with  $\leq 3^{\circ}\text{C}$  increases when scanned at 3T, and may also be safe to leave in place. This study did not address MR-related movement of these catheters.

To date, there have been no reports of harm caused by MRI in patients with epidural or peripheral nerve catheters. One case report described a patient with a retained epidural nerve catheter tip who did not have any MR-related AEs when scanned at 1.5T.<sup>13</sup> Another also reported no AEs, but with unknown catheter model and magnetic field strength.<sup>14</sup>

**TABLE 2. Recommendations of the Panel Based on Literature Review and Evidence**

<b>Recommendation</b>	<b>Panel Decision</b>	<b>Consensus Achieved at Delphi Round</b>
<b>Spinal cord stimulators with implanted pulse generators and peripheral nerve stimulators</b>		
Currently marketed spinal cord stimulators use epidural leads. If the leads are displaced to the subdural or intrathecal space, MRI could result in spinal cord injury or stimulation.	Agree	3
Trial systems and all external components of spinal cord stimulators are MR Unsafe and should be removed prior to MRI.	Agree	2
Regarding vagus nerve stimulators, except for C7-T8 or C7-L3 levels (depending on the model) which should remain outside the isocenter of the field, MRI of all other body parts is conditional at 1.5T and 3T.	Agree	1
In patients with sacral nerve stimulators, brain or spine MRI at 1.5T is not an absolute contraindication.	Agree	2
<b>Cochlear implants</b>		
With regards to screening, although currently marketed cochlear implants are MR Conditional, some of the older ones are MR Unsafe.	Agree	1
All currently marketed MR Conditional cochlear implants except the SYNCHRONY MED-EL system need removal of the internal magnet if a 3T scan is needed.	Agree	1
All currently marketed MR Conditional cochlear implants except the SYNCHRONY MED-EL system need some variation of head wrapping without removal of the internal magnet at 1.5T.	Agree	1
The SYNCHRONY MED-EL cochlear implant is MR Conditional for both 1.5T and 3T and does not need head wrapping or internal magnet removal.	Agree	1
Removal of the internal magnet of cochlear implants can improve image quality and visualization of immediately adjacent structures (i.e., ipsilateral internal auditory canal).	Agree	2
<b>Scleral buckles and retinal tacks</b>		
With regards to MRI safety, screening for scleral buckles is not necessary.	Agree	2
With regards to MRI safety, screening for retinal tacks, including model and manufacturer should be sought as some retinal tacks are not safe to scan.	Agree	2
<b>Coronary and carotid stents</b>		
With regards to MRI safety, all nonferromagnetic coronary and/or carotid stents can be scanned at 1.5T and 3T.	Agree	1
With regards to MRI safety, scanning a ferromagnetic coronary or carotid stent $\leq 6$ weeks after insertion is NOT an absolute contraindication provided whole body averaged SAR $\leq 2$ W/kg and each sequence is 15 minutes maximum.	Agree	1
<b>Legacy pacemakers, retained epicardial and abandoned intracardiac leads</b>		
With regards to MRI safety in patients with temporary transvenous pacing wires, screening (by visual confirmation, questionnaire, review of surgical reports and/or chest radiograph) is recommended.	Agree	2
Regarding patients with temporary transvenous pacing wires, MRI is unsafe.	Agree	1

TABLE 2. Continued

Recommendation	Panel Decision	Consensus Achieved at Delphi Round
Regarding retained temporary epicardial pacing wires cut at the skin, screening (by questionnaire, review of surgical reports, and/or chest radiograph if required) is NOT recommended for adults who have undergone cardiac surgery.	Agree	3
Regarding performing whole body MRI in patients with confirmed retained temporary epicardial pacing wires cut at the skin, MRI can be performed at 1.5T or 3T.	Agree	1
In the immediate post-cardiac surgery period, MRI for patients with temporary epicardial pacing wires connected to a fully functioning generator, MRI at 1.5T or 3T is unsafe.	Agree	1
Regarding MRI safety for patients with abandoned intracardiac and epicardial leads, screening (by questionnaire, review of surgical reports and chest radiograph) is required for all patients who have undergone implantation of a pacing or defibrillating device for electrical stimulation of the heart.	Agree	1
Previous guidelines and consensus documents state that abandoned intracardiac and epicardial leads are MR Unsafe; however, studies show that they may be considered MR Conditional at 1.5T.	Agree	1
MRI may be performed in a patient with a confirmed abandoned permanent intracardiac or abandoned permanent epicardial pacemaker lead at 1.5T under controlled conditions using the same safety protocols as for patients with leads attached to generators.	Agree	2
Regarding initial screening in patients with nonconditional (legacy) implanted pacemakers or implantable cardioverter defibrillators, a radiologist or health care provider should determine if MRI would provide useful information to impact management and assess alternate modalities that might provide the same information prior to approving the study.	Agree	2
The presence of abandoned or fractured intracardiac leads is not an absolute contraindication to MRI at 1.5T.	Agree	2
Electrophysiology personnel do not have to be present throughout the entire scan in patients with legacy devices. Electrophysiology personnel are needed after the scan is completed.	Agree	2
In patients with MR Conditional cardiac implantable electronic devices, studies not performed according to the anatomic or SAR limitations of the conditions of approval should be undertaken using the procedures used for patients with legacy devices.	Agree	1
A follow-up interrogation at 30 days is necessary after MRI of a patient with a legacy device.	Disagree	2
Currently there is not enough literature evidence to support that scanning legacy cardiac implantable electronic devices poses the same risks as scanning MR Conditional cardiac implantable electronic devices.	Agree	3
<b>Endoscopic hemostatic clips</b>		
Regarding endoscopic hemostatic clips, screening (by questionnaire, review of endoscopy reports and/or abdominal radiograph) is suggested for all patients who have undergone endoscopy within 2 weeks, unless endoscopy was performed at a centre known to use only MR Conditional endoscopic hemostatic clips.	Agree	2

TABLE 2. Continued

Recommendation	Panel Decision	Consensus Achieved at Delphi Round
Regarding endoscopic hemostatic clips, screening (by questionnaire, review of endoscopy reports and/or abdominal radiograph) is not necessary if endoscopy was performed >2 weeks before date of MRI.	Agree	2
Regarding performing MRI in a patient with a confirmed retained MR Unsafe endoscopic hemostatic clip, MRI can be considered at 1.5T if MRI is medically indicated, cannot be delayed, and the risk of potential complication from possible clip detachment is considered low.	Agree	1
<b>Video capsule endoscopy devices</b>		
Regarding performing MRI in a patient with a confirmed retained video capsule endoscopy device, MRI should be delayed until the device is passed, although MRI is not an absolute contraindication.	Agree	1
<b>Intrauterine and fallopian tube closure devices</b>		
With respect to modern intrauterine devices, MRI can be performed safely at 3T, with the exception of Chinese ring, which is MR Unsafe.	Agree	2
With respect to modern fallopian tube closure devices, MRI can be performed safely up to 3T.	Agree	1
<b>Bullets, shrapnel, and foreign metallic objects</b>		
If there is suspicion for intraorbital foreign metallic objects, screening with plain radiographs, low dose orbit CT, and/or review of recently obtained head CT is necessary.	Agree	2
Metallic objects embedded in vertebral bodies are not contraindications to MRI at 1.5T and 3T irrespective of their composition.	Agree	1
MRI in patients with intra-spinal bullet/shrapnel is not an absolute contraindication. For example, in patients with spinal cord injury and complete lack of motor and sensory function below the level of injury, MRI can be considered if necessary to rule out infection.	Agree	1

All recommendations achieved 100% agreement.  
MRI = magnetic resonance imaging; CT = computed tomography; SAR = specific absorption rate.

A study that included patients scanned with epidural or peripheral nerve catheters did not report any AEs as a result of the scan, although MRI safety was not the focus of the study.<sup>15</sup> Due to the limited number of studies assessing MRI

safety with these devices, screening is recommended and when present the manufacturer guidelines should be followed for the specific model.

#### Box 1 Summary of safety concerns and key recommendations for epidural and peripheral nerve catheters

Primary concerns are displacement and heating.

##### Key Recommendations

- Screening is recommended and manufacturer guidelines should be followed in accordance to the model.
- Older devices contain stainless steel showed limited deflection and rotation under 3T. The modern ones do not contain stainless steel. Some models may be safe to leave in place at 1.5T or 3T.

#### Spinal Cord Stimulators With Implanted Pulse Generators and Peripheral Nerve Stimulators (Box 2)

Nerve stimulators are used for a diverse number of indications that are constantly expanding. This section focuses on spinal cord and peripheral nerve stimulation systems, used for pain control; vagus nerve stimulation systems, used for seizure control and drug-resistant depression; and sacral nerve stimulation systems, used for bowel and bladder control. Despite indication differences, most nerve stimulators utilize similar designs and are composed of: an implantable or external pulse generator with battery; lead wires, with a variable number of

### Box 2 Summary of safety concerns and key recommendations for spinal cord and peripheral nerve stimulators

Primary concerns are heating, displacement, and unintentional stimulation and/or device alterations.

#### Key Recommendations

- Screening is recommended, and manufacturer guidelines should be followed for the specific model.
  - Currently marketed spinal cord stimulators utilize epidural leads and are MR Conditional at 1.5T. Trial systems and all external components of spinal cord stimulators are MR Unsafe.
  - Regarding vagus nerve stimulators, except for C7-T8 or C7-L3 levels (depending on the model), MRI of all other body parts is conditional at 1.5T and 3T.
  - For the LivaNova and Cyberonics (now part of LivaNova) vagus nerve stimulators, brain or spine MRI at 1.5T is not an absolute contraindication.
  - Within North America, the InterStim sacral nerve stimulator is MR Conditional for brain MRI at 1.5T only. Outside North America there are sacral nerve stimulator systems that are MR Conditional at 1.5T and 3T.
- With the exception of peripheral nerve stimulators, MRI usually should be avoided in patients with abandoned devices or components; or broken, nonfunctional, or dislocated leads as per manufacturer guidelines, and due to lack of MRI safety data. If MRI is necessary risk-benefit assessment is needed on a case-by-case basis.
  - Limited data shows retained peripheral nerve stimulator leads can be scanned at 1.5T.

electrodes; and an external console to program and adjust settings.<sup>16</sup> In general, the location of the electrode dictates type: spinal cord electrodes are implanted within the epidural space; peripheral nerve stimulation-specific leads utilize wire- or paddle-type electrodes within the extremities—note, these leads were introduced in mid-2000s as, prior to that, spinal cord leads were used; vagus nerve electrodes are placed next to the vagus nerve in the neck; and sacral nerve leads are placed along the sacral plexus, usually anterior to the S3 neural foramen. Except for vagus nerve stimulation systems, patients initially have a trial system implanted for a few weeks, prior to implantation of a permanent system.

The primary MRI safety concerns for these systems involve heating<sup>16</sup>; possible alterations to device settings, necessitating reprogramming or replacement surgery; unintentional stimulation; and torque or displacement of the implanted pulse generator.

Due to the diversity of possible configurations and ongoing developments, it is important to always check manufacturer specifications to obtain the latest device and safety information prior to scanning. According to all current manufacturer guidelines, MRI should usually be avoided in patients with abandoned devices or components; or broken, nonfunctional, or dislocated spinal cord, vagus nerve, or sacral nerve stimulation components. No literature reports were found where MRI safety was assessed with abandoned devices or components. Devices with external or removable pulse generators have fewer restrictions compared with

traditional neuromodulation systems.<sup>17</sup> All current manufacturer guidelines state that the trial systems and external components of all permanent systems are MR Unsafe.

### SPINAL CORD STIMULATION SYSTEMS WITH IMPLANTED PULSE GENERATORS.

Historically, the presence of a spinal cord stimulation system with an implanted pulse generator has been considered a contraindication for MRI. Technological improvements have led to the development of systems that are MR Conditional following specific parameters, as outlined in manufacturer IFUs. When scanning patients with these devices at 1.5T, the most commonly reported side effect during MRI is transient warmth at the implanted pulse generator or electrode, which was insufficient to cause burns.<sup>18,19</sup> In one report, two patients could not have telemetry performed after 1.5T MRI; however, this was attributed to total battery exhaustion rather than an MRI-induced effect.<sup>19</sup> No serious AEs have been reported. No reports were found on patients undergoing MRI with newer systems that utilize high-frequency stimulation such as the Senza (Nevro, Redwood City, CA). If the epidural leads are displaced into the subdural or intrathecal space, MRI could result in spinal cord injury or stimulation (Table 2). There is ongoing research for subdural spinal electrodes (NCT03380104).

**PERIPHERAL NERVE STIMULATION SYSTEMS.** When spinal cord stimulation system electrodes are used off-label as peripheral nerve stimulation system leads, it is important to know the electrode model and consult the IFU prior to MRI. Peripheral nerve stimulators with implanted pulse generators should generally undergo the same considerations as those outlined for spinal cord stimulation systems with implanted pulse generators; therefore, this section will only encompass dedicated peripheral nerve stimulation systems with external pulse generators.

SPR Therapeutics (Cleveland, OH) have approved leads that are MR Conditional at 1.5T, although testing has shown that 3T scans are feasible.<sup>20</sup> Similarly, StimWave Technologies (Pompano Beach, FL) have peripheral nerve stimulation system leads that are MR Conditional at 1.5T, while Bioness (Valencia, CA) has a lead that is MR Conditional at 1.5T and 3T; these are currently the only companies with FDA approval for their systems. One study examined the MRI safety of retained fragments of SPR Therapeutics peripheral nerve stimulator leads and found that 1.5T scans can be safely performed,<sup>20</sup> although no studies on the retained leads from other manufacturers were found.

In Europe, BlueWind Medical (Herzliya, Israel) have approved leads that are MR Conditional at 1.5T and 3T.

### IMPLANTABLE VAGUS NERVE STIMULATION SYSTEMS.

The existing implantable vagus nerve stimulation systems are from LivaNova (London, UK) and Cyberonics (now part of LivaNova, London, UK). Both are MR Conditional at 1.5T



### Box 3 Summary of safety concerns and key recommendations for cochlear and auditory brainstem implants

Primary concerns are dislocation of internal magnet. Less commonly demagnetization or reversal of the magnet may occur.

#### Key Recommendations

- Recommendations apply to both cochlear and auditory brainstem implants.
- Screening is recommended and the manufacturer guidelines should be followed for the specific model. Some of the older cochlear implant models are MR Unsafe.
- Except the SYNCHRONY MED-EL system, all currently marketed cochlear implants require some variation of a head wrap when scanned with the internal magnet; additionally, the internal magnet needs to be removed for 3T MRI.
- The SYNCHRONY MED-EL cochlear implant is MR Conditional for both 1.5T and 3T and does not need head wrapping or internal magnet removal.
- Magnet dislodgement can be confirmed with Stenvers-view radiographs.

and 3T for brain and extremities MRI. Depending on the stimulator, the manufacturer states the scan isocenter should exclude C7-T8 or C7-L3. *In vitro* tests support this exclusion, as the leads may excessively heat.<sup>21</sup> No serious AEs have been reported when scanning under these conditions.<sup>22,23</sup>

#### IMPLANTABLE SACRAL NERVE STIMULATION SYSTEMS.

Currently, InterStim from Medtronic (Fridley, MN) is the only FDA-approved system and is MR Conditional for brain imaging at 1.5T only, with no serious AEs reported. Although nonbrain MRs are contraindicated per the manufacturer's guidelines, it is feasible for patients to undergo cervicothoracic<sup>24</sup> and lumbrosacral spine MRI<sup>25</sup> under controlled conditions. Axionics Modulation Technologies (Irvine, CA) has an r-SNM System that is MR Conditional in Europe, Australia, and Canada, with varying MRI guidelines for field strength and MRI type depending on the geographic region; clinical trials are underway to support its FDA approval (NCT02620410, NCT03327948). However, no clinical studies on the MRI safety of the r-SNM System could be found.

**COCHLEAR IMPLANTS (BOX 3)** Cochlear implants are used to treat moderate to profound bilateral sensorineural hearing loss and single-sided deafness.<sup>26</sup> Products from Cochlear (Sydney, Australia), Advanced Bionics (Stafa, Switzerland), and MED-EL (Innsbruck, Austria) have FDA approval. Oticon Medical (Vallauris, France) is also a common manufacturer outside the US.

The system generally consists of an external audio processor and coil transmitter, and a subcutaneously implanted receiver coil and stimulator unit. The audio processor can be a separate earpiece or integrated with the external coil. The external coil is magnetically mounted over the internal magnet within the implanted coil, which stimulates the cochlear nerve within the cochlea.

The main concerns with MRI are dislocation or movement of the internal magnet causing pain or device

dysfunction. Less common AEs include demagnetization<sup>27</sup> or reversal of polarity of the internal magnet.<sup>28</sup>

All external components of cochlear implant devices are MR Unsafe. The internal components of currently marketed devices with the internal magnet in place are MR Conditional at 1.5T as long as patients are given some variation of compression wrap and splint for their head. There are reported cases of dislocation or tilting of the internal magnet despite the compressive bandage,<sup>28–30</sup> although patients with Oticon Medical's Neuro Zti have been scanned at 1.5T with no AEs, with or without head wrap.<sup>31</sup> Caution should be used when a patient presents with an older model, as some that are no longer marketed in North America, including Cochlear's CI22M, Advance Bionics CLARION, and HiResolution 90K series, have different MRI safety guidelines.

The FDA-approved cochlear implants listed above and the Neuro Zti are also MR Conditional at 3T with the internal magnet removed. MED-EL's latest device, the SYNCHRONY, is MR Conditional at 1.5T and 3T with the magnet in place. No compressive wrap is needed, as it has a rotatable and diametrically magnetized internal magnet which should prevent its dislocation. No AEs have been reported for patients with SYNCHRONY when scanned at 3T.<sup>26,30</sup>

Identification of the implant model is important prior to MR scanning. At 1.5T the internal magnet may be left in, or it can be surgically removed if the patient experiences symptoms of dislodgement. Except for MED-EL's SYNCHRONY, all internal magnets should be removed for 3T scans. If there is suspicion of magnet dislodgement during or after the MRI, which is almost always accompanied by patient discomfort, a Stenvers-view radiograph, in which the head is angled 45° from the anteroposterior position and X-ray beam is angled 12° cephalocaudally,<sup>32</sup> should be performed to confirm internal magnet location and position.

The effect of MRI on cochlear implants when scanning nonbrain body parts should be considered. If the implant is located near the entrance of the MRI bore, as in abdominal imaging, changes in spatial static and time-varying gradient fields are higher than when the brain is near the isocenter of the magnet. This will increase the possibility of internal magnet movement.<sup>30</sup> Cochlear implant magnets cause significant

### Box 4 Summary of safety concerns and key recommendations for retinal detachment devices

There are no concerns with regards to scleral buckles. The primary concern with some retinal tacks is dislodgement.

#### Key Recommendations

- Screening for scleral buckle is not necessary.
- Presence, model and manufacturer of retinal tacks should be sought as some retinal tacks are not safe to scan.
- Retinal tacks used to secure components of the retinal prosthesis system, Argus II, are MR Conditional at 1.5T and 3T.

local field inhomogeneities and image artifacts, especially within the ipsilateral brain and structures such as the internal auditory canal; in these cases, the internal magnet may have to be removed to reduce artifacts.

When the cochlear nerve is nonfunctional, absent, or destroyed, an auditory brainstem implant may be implanted. The main indication for its use is neurofibromatosis type 2 with bilateral vestibular schwannomas, so they are less commonly seen compared to cochlear implants. However, like cochlear implants, auditory brainstem implants are also comprised of external and implanted components containing an internal coil and magnet; the main difference is that the implanted electrode is placed over the surface of the brainstem. Nucleus ABI541 and ABI24M (Cochlear) are FDA-approved auditory brainstem implants, are MR Conditional at 1.5T with the magnet in, and MR Conditional at 3T with the magnet removed. Several other companies offer their own variation of the auditory brainstem implant,<sup>33</sup> including the Digisonic SP ABI (Oticon Medical) and the SYNCHRONY ABI system (MED-EL). Given the similarities between cochlear and auditory brainstem implants, the same considerations should be taken into account when assessing MRI safety.

#### **Scleral Buckles and Retinal Tacks (Box 4)**

Scleral buckling has been performed since the 1930s. It involves suturing a silicone band onto the sclera to treat retinal detachment. Historically, tantalum clips were used to fasten the free-ends of the band, but currently sutures-only are preferred.<sup>34</sup> No reports on the use of metallic nontantalum clips for scleral buckling were found in the literature. No reports of AEs have been reported in patients scanned with tantalum clips, and testing has shown that they do not exhibit any ferromagnetism at 1.5T.<sup>35</sup> Given the lack of risks associated with tantalum clips, the absence of evidence for use of any metallic nontantalum clips, and lack of any reported AEs in patients who had undergone scleral buckling, screening for these are not necessary (Table 2).<sup>35</sup>

Retinal tacks are used to repair retinal detachments and allow immediate fixation of the retina. They are ~1 x 3 mm and have a conical configuration with the sharply-pointed

end inserted into the retina. They can be composed of a wide range of metallic and nonmetallic materials. Although largely unused since the 1980s, many commonly employed metallic retinal tacks are MR Conditional at 1.5T, with one exception being Western European-type retinal tacks manufactured from martensitic stainless steel.<sup>36,37</sup> This retinal tack has the potential to become completely dislodged when placed in the magnetic field of 1.5T scanners, although this movement was not sufficient to cause retinal tear or intraocular damage when tested in rabbits.<sup>36</sup> Due to the limited number of studies, these should be considered MR Unsafe and patients should be screened to identify MR Unsafe models. No studies examining heating of retinal tacks or case studies showing patient harm were identified. Recently, custom-made MR Conditional titanium retinal tacks are used to secure components of the retinal prosthesis system, the Argus II,<sup>38</sup> and no AEs have been reported in patients undergoing MR at 1.5T or 3T with these.<sup>39</sup>

#### **Coronary and Carotid Stents (Box 5)**

Coronary stents were invented in the 1980s to prevent restenosis of arteries after balloon angioplasty.<sup>40</sup> The initial cardiac stents were permanent bare metals made of alloys such as stainless steel and cobalt-chromium. In the 2000s, there was an attempt to improve upon the restenosis rate with drug-eluting stents made of the permanent bare metal and a polymer overlayer.<sup>41</sup> The next generation of cardiac stents includes bioabsorbable stents based on magnesium alloys with a poly-L-lactic acid polymer coating.<sup>40</sup> The primary MRI-related concerns are stent displacement and RF-induced heating.

Most currently marketed and available carotid stents are made of nitinol, 316L stainless steel, or a cobalt alloy.<sup>42</sup> Less commonly, they are made of alloys including platinum, carbon, gold, MP35N, or tantalum.<sup>42,43</sup> Most coronary and carotid stents exhibit nonferromagnetic or weakly ferromagnetic behavior at both 1.5T and 3T.<sup>41,44,45</sup>

The implantation of coronary and/or carotid stents into the vessel wall during the interventional procedure immediately anchors the stent, with additional tissue in-growth occurring 6–8 weeks later. The forces caused by the magnetic field on the stents have been clinically shown to be insufficient at 1.5T or 3T to cause movement. In Hug et al, ex vivo testing on 19 different coronary arterial stents demonstrated 2/19 as nonferromagnetic and 17/19 as minimally ferromagnetic, with no device migration or significant heating.<sup>46</sup> Subsequent studies have confirmed the safety of both bare metal and drug-eluting cardiac stents immediately after implantation.<sup>41,47</sup> Therefore, there is no compelling data to support delaying MR imaging for 6–8 weeks after stent deployment.<sup>45,48</sup>

Regarding RF-induced heating, no clinically significant temperature alterations have been observed in stents,

#### **Box 5 Summary of safety concerns and key recommendations for coronary and carotid stents**

Primary concerns are displacement. No studies have found concern with heating.

##### Key recommendations

- The date of stent placement and device manufacturer should be ascertained.
- Patients with unknown model coronary or carotid stents can be scanned with whole-body-averaged SAR  $\leq 2$  W/kg and maximum 15 minutes per sequence. MRI can be performed in patients with weakly ferromagnetic coronary and carotid stents at 1.5T or 3T six weeks after implantation. Scanning these patients without a 6-week delay can be considered on a case-by-case basis.

with only minimal heating  $<1^{\circ}\text{C}$  for a single stent and  $<2^{\circ}\text{C}$  for overlapping stents.<sup>42</sup> No studies have shown an increased risk of stent-related subacute or late thrombosis attributable to MRI.<sup>48,49</sup> A retrospective review of patients with myocardial infarction who underwent MRIs within 2 weeks (median 3 days) of stent placement detected no increased incidence of AEs at 30 days or 6 months compared with patients who had not undergone MRI.<sup>50</sup>

Due to their metallic composition, all coronary and carotid stents are MR Conditional.<sup>43-45</sup> Prior to MRI, the date of stent placement should be obtained and the IFU followed, as certain stents have labeling that allow for whole-body average SAR of 4 W/kg. Comparatively, patients with an unknown stent model can be scanned with whole-body-averaged SAR  $\leq 2$  W/kg and maximum 15 minutes per sequence. All nonferromagnetic coronary and carotid stents can be scanned at 1.5T or 3T immediately after placement. MRI can be safely performed in patients with weakly ferromagnetic stents at 1.5T or 3T 6 weeks after implantation; scanning these patients without a 6-week delay can be considered on a case-by-case basis (Table 2).

Finally, there may be local artifacts generated within the lumen of the stent on MRI, limiting determination of in-stent patency or thrombosis depending on the stent type.<sup>45</sup>

### **MR Nonconditional (Legacy) Pacemakers and Defibrillators (Box 6)**

Nonconditional or legacy cardiac implantable electronic devices (CIEDs) include pacemakers, implantable cardioverter defibrillators (ICDs), and associated leads that have not been specifically approved for use in the MRI environment. As many CIEDs have been approved as pairs of specific pulse

generators and leads, the nonconditional category includes conditional generators that have been attached to nonconditional leads (or, rarely, vice versa), or generator-lead pairs that were not specifically approved for use together. In addition, as devices are only approved for use under specific scan conditions, any scan performed outside these conditions will render the device nonconditional for that scan. Although many newly implanted pacemakers and ICDs are MR Conditional, it is estimated that approximately 6 million patients have legacy devices and 50–75% will have a clinical indication for MRI during the lifetime of the device.<sup>51</sup>

There are several potential safety concerns when performing MRI in patients with legacy CIEDs, as interactions can occur between the device and various components of the MRI system, including the static magnetic, RF, and gradient fields. These interactions can result in changes in pacing threshold, inhibition of pacing output, inappropriate pacing, activation of asynchronous pacing (magnet mode), inappropriate ICD discharges, decrease in lead impedance, and changes in P- and R-wave amplitude.<sup>52</sup> A power-on or reset can occur in devices manufactured before 2002, leading to a change from asynchronous to inhibited pacing (VVI mode), inducing bradycardia in pacemaker-dependent patients, causing inappropriate antitachycardia pacing or shocks to patients with ICDs, or battery depletion.<sup>53</sup> Physical effects including device or lead movement, heating of the lead electrodes and tissue injury, potential tissue ablation, higher battery utilization, and device failure are other potential complications. Additional risks for legacy ICDs include increased physical effects related to the larger device relative to pacemaker generators and leads, and susceptibility to arrhythmia while tachycardia detection and therapies are turned off for MRI.<sup>54</sup>

Despite early reports of fatalities related to MRI in patients with legacy CIEDs,<sup>55</sup> many groups began to report scanning patients with legacy devices without incident beginning in the early 2000s. Recent publications, including two in 2017 comprising nearly 3000 scans,<sup>56,57</sup> have resulted in several new specialty society guidelines.<sup>8,58</sup> In general, scanning patients with legacy devices is supported following screening if: 1) MRI field strength is  $\leq 1.5\text{T}$  using Normal Operating Mode; 2) the implanted CIED has no fractured or abandoned intracardiac leads (please see "Abandoned Epicardial Pacer Wires and Abandoned Leads" regarding scanning patients with abandoned leads); and 3) the facility has implemented a checklist process that includes the following steps: assessment to identify the presence of a CIED; obtaining informed consent; the CIED is interrogated and programmed appropriately based on device and patient characteristics; the scan is supervised by an experienced practitioner and advanced cardiovascular life support (ACLS)-certified provider, with equipment to monitor vital signs and cardiac rhythm; and that the CIED is evaluated prior to discharge to ensure correct function and no abnormalities

#### **Box 6 Summary of safety concerns and key recommendations for legacy pacemakers, retained epicardial pacer wires, and abandoned intracardiac leads**

Primary concerns are changes in the setting of pacemaker system and inappropriate pacing, heating, and movement of the leads.

##### **Key Recommendations**

- In patients with retained temporary epicardial wires cut at the skin, no screening is necessary and whole-body MRI can be performed at 1.5T or 3T.
- With regards to MRI safety in patients with temporary transvenous pacing wires, MRI is unsafe.
- Previous guidelines and consensus documents state that abandoned intracardiac and epicardial leads are MR Unsafe; however, studies show that they may be considered MR Conditional at 1.5T, SAR  $\leq 1.5$  W/kg, and using the same safety protocols as patients with leads attached to generators. [Correction added on October 4, 2019, after first online publication: In the preceding sentence, the SAR unit was corrected.]
- In patients with MR Conditional cardiac implantable electronic devices, the procedures used for patients with legacy devices should be used when performing scans outside the prescribed SAR and anatomic limitations.
- When scanning patients with legacy devices, electrophysiology personnel are only needed after the scan is completed but they should be on-call. They do not need to be present during the scan and a follow-up at 30 days is not necessary.

occurred during the scan. Following these guidelines and manufacturer IFUs, electrophysiology personnel do not have to be present during the scan but should be on-call (Table 2). Devices should be checked by electrophysiology personnel after the scan, although routine follow-up interrogation is not necessary at 30 days following the scan (Table 2).

### **Retained Epicardial Pacer Wires and Abandoned Pacemakers Leads (Box 6)**

**TEMPORARY EPICARDIAL PACING WIRES.** Temporary epicardial pacing wires are routinely placed to diagnose and treat arrhythmias in the early postoperative period of patients who underwent cardiac surgery.<sup>59</sup> These are designed for temporary use<sup>59</sup> and are typically removed within a week of surgery; however, sometimes they can be difficult or impossible to remove. In such cases, they are cut at the skin surface and retained. Therefore, the retained wires may be of varying lengths.

Temporary epicardial pacing wires are composed of stainless-steel multithread conductors surrounded by an external insulating sheath. Theoretical risks of performing MRI on patients with retained temporary epicardial pacing wires include cardiac excitation<sup>60</sup> and thermal injury. In a study of 51 subjects undergoing MRI at 1–1.5T, diagnostic imaging was obtained in all but two patients who underwent cardiac MRI for investigation of underlying etiology of ventricular arrhythmia. In those two patients, their baseline arrhythmia led to poor cardiac gating, rendering their imaging nondiagnostic.<sup>61</sup> Susceptibility effects related to the retained wire did not interfere with image quality.<sup>61</sup> The authors argued that the currents and voltage required to cause arrhythmias are higher than those likely to be generated with the shortened lengths of retained temporary epicardial pacing wires.<sup>61</sup> However, that study did not address technical parameters such as RF deposition and exact anatomic location of scanning.<sup>60</sup> Despite low-level evidence, because of the relatively low risk of complications, expert multidisciplinary consensus supports 1.5T and 3T MRI in any body part without routine screening of patients with retained temporary epicardial pacing wires.<sup>42</sup> In support of that consensus recommendation, there have been no reported serious complications from scanning patients with retained temporary epicardial pacing wires.

**TEMPORARY TRANSVENOUS PACING LEADS.** Temporary transvenous pacing leads are used for single- or dual-chamber pacing in a controlled environment where continuous monitoring is available. Leads made after 1995 have limited, or no, ferromagnetic material, so displacement is not a concern.<sup>62</sup> However, they have been shown to heat up to 20°C in an *ex vivo* animal tissue study, but without resultant tissue damage.<sup>63</sup> The leads are prone to induction of a current even when scanning without the generator. Therefore, temporary

percutaneously placed transvenous pacemakers are considered MR Unsafe and labeled by the vendors as such.<sup>42</sup>

### **ABANDONED PERMANENT INTRACARDIAC AND ABANDONED PERMANENT EPICARDIAL PACING LEADS.**

Permanent pacemakers are composed of a generator and intracardiac leads, the latter of which pass into and remain embedded in the myocardium. The intracardiac leads may fracture, dislodge, or fail to properly function due to a number of factors and require replacement over time.<sup>64</sup> Some leads are too high-risk to remove without causing a complication. In such cases, they are disconnected from the pulse generator and typically capped with plastic to reduce risk of inadvertent excitation.<sup>64</sup> Less commonly encountered are abandoned permanent epicardial pacing leads, which are typically placed in pediatric patients.<sup>65</sup>

An *ex vivo* study demonstrated that abandoned and pacemaker-attached leads show RF-induced heating. For clinical lead lengths of 40–60 cm, abandoned leads exhibit greater lead tip heating compared with pacemaker-attached leads.<sup>64</sup> The coupling of the RF field to the pacemaker lead is determined by the amplitude and phase of the electric field along the lead and its length, which results in heating at the lead tip—the portion implanted in myocardium.<sup>64</sup> One author argues in response to these findings that RF field risk is actually reduced for abandoned leads because: 1) the abandoned lead acts as an open circuit rather than the short circuit that forms when attached to a pulse generator; 2) the field coupling mechanism is reduced if the lead is fractured or insulation breaks down; 3) dislodgement to nonexcitable tissue or abnormalities in pacing and sensing will not destroy excitable tissue but mostly scar tissue; and 4) power density around the lead tip decreases with the fourth power of the distance or a distance equal to tip radius.<sup>66</sup>

Retrospective studies of patients with abandoned leads scanned at 1.5T and SAR  $\leq 1.5$  W/kg reported no AEs.<sup>67–69</sup> One study showed no significant change in function in patients who underwent MRI and had leads later reconnected

#### **Box 7 Summary of safety concerns and key recommendations for endoscopic hemostatic clips**

Primary safety concerns are mostly theoretical and concern heating.

##### Key Recommendations

- Screening for endoscopic hemostatic clips is suggested for all patients who have undergone endoscopy within 2 weeks, unless endoscopy was performed at a center known to use only MR Conditional endoscopic hemostatic clips. It is not necessary if endoscopy was performed >2 weeks before MRI.
- MRI can be considered at 1.5T in patients with retained MR Unsafe endoscopic hemostatic clips if MRI is medically indicated, cannot be delayed, and the risk of potential complication from possible clip detachment is considered low.
- The presence of retained endoscopic clips can be confirmed by radiography.

**Box 8 Summary of safety concerns and key recommendations for video capsule endoscopic recording devices**

Primary safety concerns are mostly theoretical and concern heating.

**Key Recommendations**

- MRI should be delayed until video capsule endoscopy device has been passed, although MRI is not an absolute contraindication.
- The presence of video capsule endoscopic recording devices can be confirmed by radiography.

to a pulse generator.<sup>67</sup> While previous guidelines and consensus documents have stated that abandoned leads are an absolute contraindication to MRI, these studies suggest that they should be considered MR Conditional at 1.5T and SAR  $\leq$ 1.5 W/kg. There is no need for additional monitoring beyond standards set for imaging patients with permanent leads attached to generators.<sup>69</sup>

**Endoscopic Hemostatic Clips and Video Capsule Endoscopic Recording Devices (Boxes 7 and 8)**

Endoscopic hemostatic clips are used to control gastrointestinal bleeding; secure feeding tubes, endoluminal stents, and catheters; close mucosal defects, perforations, and anastomotic leaks; and mark tumors prior to surgery or radiotherapy.<sup>70</sup> MR Unsafe endoscopic hemostatic clips include older generation clips from Olympus America (Center Valley, PA), and the QuickClip, LongClip, and TriClip from Cook Endoscopy (Bloomington, IN).<sup>71</sup> Modern endoscopic clips, including the QuickClip Pro (Olympus America), Instinct Clip (Cook Endoscopy), Resolution clip (Boston Scientific, Marlborough, MA), and LIGACLIP (Ethicon Endo-Surgery, Blue Ash, OH), are MR Conditional up to 3T according to IFUs. Studies evaluating the MRI safety of endoscopic hemostatic clips are limited. A single case report published in 2014<sup>72</sup> describes a patient death from cardiopulmonary arrest associated with hematemesis presumed to be due to rebleeding from a laceration below the esophageal sphincter. The laceration was treated with an endoscopic clip (Instinct, Cook Endoscopy) and rebleeding occurred immediately following brain MRI, which was performed 6 days after endoscopy. The authors attributed the rebleeding to clip migration during the MRI; however, this was not confirmed radiographically or with autopsy. The authors did later physically test the endoscopic clip in their MR environment, with no indication of MRI field strength, and reported significant movement of the clip in the MRI. The device in question is considered MR Conditional up to 3T according to manufacturer specifications. Due to the lack of MRI safety data reported in that study, the authors question whether there were alternative reasons that resulted in the patient death. No other reports of AEs from retained endoscopic hemostatic clips in patients who underwent MRI at any field strength. To our knowledge, there are no studies formally evaluating the heating effects of

endoscopic hemostatic clips under MRI and the potential associated risk to the gastrointestinal tract wall; however, this concern appears mainly theoretical. Most endoscopically-placed hemostatic clips detach and are passed in bowel movements within 2 weeks of placement. The Resolution clip is known to have the longest attachment, lasting up to 5 weeks in 100% (5/5) of animals studied.<sup>70</sup> Cases of endoscopic hemostatic clips retained years after placement have been reported but are rare.<sup>73,74</sup>

Although there is a wide variance in screening policies,<sup>71</sup> in the case of patients who were imaged at a facility that uses nonconditional hemostatic clips or where the type of clip used is unknown, these patients should be screened to assess whether endoscopy was performed within 2 weeks of MRI, as patients may be unaware of its placement (Table 2). The presence of a hemostatic clip can be confirmed with radiography.<sup>75</sup> For patients who are imaged at a facility that uses only MR Conditional hemostatic clips, screening patients is of no value (Table 2). It should be acknowledged, however, that the presence of a retained clip, which can be detected at time of MRI, may limit the diagnostic accuracy of the scan.

**Video Capsule Endoscopic Recording Devices (Box 8)**

Video capsule endoscopy (VCE) provides a noninvasive method for visualization of the small intestine beyond what can be reached through traditional upper endoscopy or colonoscopy and can be used to assess a myriad of small-bowel disorders.<sup>76</sup> VCE devices are wireless and generally consist of a capsule containing one or more video cameras, a video chip, batteries, and an electronic circuit to either store or transfer data to an external recorder, either by RF waves or electrical current.<sup>77</sup> Data regarding VCE devices and MRI safety are scarce. VCE devices are considered MR Unsafe<sup>77</sup> because of an unknown risk to the bowel wall due to heat or high forces exerted on the device. Additionally, in patients who underwent MRI with retained VCE, no diagnostic information could be retrieved from the VCE, possibly due to an interaction between the VCE transmission of data and MRI.<sup>77</sup>

**Box 9 Summary of safety concerns and key recommendations for Intrauterine and Fallopian Tube Closure Devices**

Primary concerns are dislocation, rotation, and heating of the devices as well as perforation of female reproductive structures.

**Key Recommendations**

- Hormone-based intrauterine devices (IUDs) are MR Safe.
- All currently marketed metallic IUDs are MR Conditional up to 3T.
- The Chinese Ring is MR Unsafe and can be detected with abdominal radiography due to its distinct circular or circular braided appearance.
- MRI can be performed safely up to 3T for patients with fallopian tube closure devices.
- Subcutaneous birth control implants are MR Safe.

Therefore, MRI ideally should be delayed until the VCE has passed; however, there are no documented instances of harm in a patient with a retained VCE undergoing MRI.<sup>77</sup> If MRI cannot be delayed until the VCE has passed and is deemed necessary for clinical care, then retrieval prior to MRI is recommended. If the VCE is irretrievable, MRI could be considered but it should be acknowledged that the device would likely be damaged, VCE data lost, and that the evidence for safety is limited. In cases where VCE is chronically retained, it is likely that the VCE is not functional and should not be considered an absolute contraindication for MRI (Table 2). Screening for VCE devices can be accomplished by a screening questionnaire; however, if there is any doubt, abdominal radiography can be performed to confirm passage of a VCE device.

### **Intrauterine and Fallopian Tube Closure Devices (Box 9)**

Intrauterine devices (IUDs) are commonly used and are either hormone- or metallic- based. IUDs that function by inducing hormonal effects are composed of plastic and do not include any metallic, magnetic, or conductive materials. Therefore, hormone-based IUDs are considered MR Safe. Comparatively, metallic IUDs are typically made with plastic and are wrapped in either copper, gold, or steel and therefore are the focus of this section. Copper is the most commonly used metal, with up to 380 mm<sup>2</sup> surface area on IUDs. Although there is a paucity of literature addressing the MRI safety of IUDs, primary concerns include heating, dislocation, rotation, and perforation of the uterine wall, which may result in bleeding or pelvic inflammatory disease.

Despite limited studies testing MRI safety of IUDs at 1.5T or 3T, no reports of AEs were found for IUDs made with copper or gold.<sup>78,79</sup> According to various manufacturers' recommendations, all currently marketed metallic IUDs are MR Conditional up to 3T. Some discontinued IUDs, such as the Gyne T 380 (Cilag, Sulzbach, Germany) have not been tested at 3T but are MR Conditional at 1.5T; nevertheless, given its similar composition and shape to current copper IUDs, it may be considered MR Conditional at 3T.<sup>80</sup> However, over a decade has passed since its discontinuation and it is unlikely any women still have this IUD *in situ*.<sup>81</sup> Notably, the Chinese Ring is a stainless steel IUD ring used in China from 1980–2000 and is considered MR Unsafe at any field strength due to its potential for displacement and rotation. If present, it should be removed prior to MRI.<sup>78</sup> Although the use of this IUD was discontinued in 2000, its 5- to 20- year lifespan raises the potential that some women may still have the device *in situ*. Screening for this device in the appropriate population is preferred. If there is any doubt about its presence, it can be detected with abdominal radiography due to its distinct circular or circular braided appearance. For all other IUDs, no AEs when scanning up to 3T have been reported.<sup>78,79</sup> Of note, the copper IUDs Mona Lisa NT Cu380

(Mona Lisa, Belgium), LevoCept, and VeraCept (Sebla Pharmaceuticals, Roswell, GA) are currently undergoing clinical trials for FDA approval (NCT03124160, NCT02882191, and NCT03633799, respectively). No MRI safety concerns are expected with the Mona Lisa NT Cu380 when scanning at  $\leq 3T$ .<sup>78</sup> The LevoCept and VeraCept are made of a nitinol wire lead and are not expected to have MRI safety concerns.

Fallopian tube closure devices are permanent female sterilization devices; therefore, although some devices have since been discontinued, they will be described here. Adiana (Hologic, Marlborough, MA) and Ovabloc/Ovalastic (Urogyn, The Netherlands) are made of nonmetallic materials and are MR Safe. Essure (Bayer, Pittsburgh, PA) is a stainless steel coil wrapped within a nickel-titanium alloy outer coil. It is MR Conditional at 1.5T<sup>82</sup> and 3T as per the manufacturer IFU. The Filshie Clip (CooperSurgical, Trumbull, CT), Hulka Clip (R. Wolf Medical Instruments, Vernon Hills, IL) Tubal Ligation devices, and AltaSeal (AltaScience, Ireland) are MR Conditional up to 3T.

Although not located in the uterus or fallopian tubes, subcutaneous birth control implants are a related consideration. The implants currently on the market are not metallic and therefore have no MR-related restrictions.

### **Bullets, Shrapnel, and Foreign Metallic Objects (Box 10)**

Bullets and shrapnel are commonly seen in victims of war, gang violence, and domestic violence. Foreign metallic objects (FMOs) may result from previous injury or metalwork. The prevalence of FMOs is ~0.20% in the general population.<sup>83</sup>

The primary concerns with regard to MRI safety revolve around object composition, as ferromagnetic materials have the potential to migrate, rotate, or heat. Nonferromagnetic materials may also undergo RF-induced heating. Regardless of composition, shape, and size, the presence of sharp edges and location of the object should also be considered during risk assessment.

#### **Box 10 Summary of safety concerns and key recommendations for metallic foreign objects (FMOs)**

Primary concerns are displacement and rotation. Temperature increases are only a concern when FMOs >3 cm.

##### **Key Recommendations**

- When the composition is unknown, it should always be considered ferromagnetic during risk assessment.
- The location and shape of FMO can be assessed via x-ray prior to MR scan if not known.
- FMOs embedded in vertebral bodies are not contraindications to MRI at 1.5T and 3T irrespective of their composition. There is insufficient data to comment about the safety of FMOs embedded in soft tissue, therefore patients with these should be considered on a case-by-case basis.
- If there is suspicion for intraorbital FMOs, screening with plain radiographs, low dose orbit CT, and/or review of recently obtained head CT is necessary.

Several studies have shown that ferromagnetic bullets have the potential to migrate up to 10 cm in gelatine structures and show significant rotation at both 1.5T and 3T.<sup>84–86</sup> However, nearly all nonsteel and nonnickel containing bullets showed no migration or rotation in magnetic fields up to 7T.<sup>84,87,88</sup> Although one study found nonsteel bullets could migrate and rotate, the authors suggested that this could be due to metallic impurities.<sup>89</sup>

Measures of temperature changes have demonstrated a maximum increase of 1.7°C at 3T irrespective of bullet composition, which was not significantly different compared with the background temperature rises.<sup>88</sup> Therefore, MR-related heating of bullets is not of clinical concern, unless the FMOs are >3 cm.<sup>90</sup> FMOs outside the RF field are unlikely to heat.<sup>75</sup>

If the composition is not clear, it should be presumed to be ferromagnetic for risk assessment. Movement or rotation of FMOs could damage nearby vital structures, particularly spinal cord and great vessels. Historically, patients with bullets, shrapnel, or FMOs located inside the spinal canal are considered unsafe for MRI, but some studies suggest that 1.5T spinal MRIs in patients with nonferromagnetic bullets or shrapnel lodged near the spinal cord may be safely performed.<sup>85,91,92</sup> Additionally, patients with bullet or shrapnel embedded in bone are safe to be scanned, but there is insufficient evidence that fibrous soft tissue around bullets, shrapnel, or FMOs can safely limit movement.<sup>89</sup> Lastly, the shape of the object, including its orientation and margins, should be considered. Spherical objects (ie, BB bullets and shotgun pellets) lack a rotational axis but may demonstrate increased longitudinal movement as a result. Nonspherical objects rotate to align with the magnetic field, with increased torque observed in stronger magnetic fields.<sup>86</sup> Elongated FMOs in particular exhibit increased torque and rotation tendencies.<sup>93</sup> Movement of objects with jagged or sharp margins or pointed edges could result in patient injury.

When there is suspicion or knowledge of an FMO, thorough screening using patient history and previous imaging for risk assessment is recommended. If there is still doubt after screening, radiographs can help assess the size and location of the FMO. Safety practices that utilize handheld and full body sensors for metallic and ferromagnetic materials have been shown to reliably detect FMOs.<sup>94</sup> However, caution is advised, as it is possible these devices may not be able to detect small ferromagnetic fragments adjacent to sensitive organs.

**INTRAOBITAL FMOs.** Intraorbital FMOs have the potential to damage the eye and cause blindness, but prevalence is rare.<sup>95</sup> The first serious AE was presented by Kelly et al,<sup>96</sup> where the MRI of a patient with a 2 x 3.5 mm intraorbital FMO resulted in unilateral blindness.<sup>96</sup> Subsequent reports on AEs have been rare, and have not resulted in serious or

permanent harm.<sup>97–100</sup> One study reported that two patients with small ( $\leq 0.5$  mm) intraorbital ferromagnetic FMOs did not experience any clinical consequence when scanned at 1.0T,<sup>101</sup> but due to the limited number of human studies the authors suggested that a thorough screening be performed when there is suspicion of intraorbital FMOs. Patients should be questioned about known intraorbital FMOs for which medical attention was sought. In such circumstances, existing imaging (eg, head CT) or, if necessary, 2-view x-ray orbit films<sup>5</sup> or low-dose orbit CT can be used for confirmation (Table 2). However, CT can detect very small metallic fragments not visible on plain radiographs that do not have enough mass to be of clinical significance, and therefore the CT should be interpreted with caution regarding MRI safety.

## LIMITATIONS

The Delphi method is an iterative process that utilizes repeated rounds and is particularly effective for establishing agreement in areas where it did not previously, or necessarily, exist,<sup>102</sup> as in MRI safety. Although we were able to achieve 100% consensus on our recommendations, the results of this study were based on a limited number of experts and may not be representative of all MRI safety professionals. Furthermore, limiting our questionnaires to dichotomous answers may have forced authors to generalize their recommendations to achieve 100% consensus. However, the use of a third-party facilitator to generate semistructured teleconferences where discussions on the recommendations could be held should have limited this, while also reducing peer pressure to concur with individuals.

## CONCLUSION

New devices are continually introduced that pose ongoing challenges for MR professionals who need to ensure device compatibility prior to MRI. This review presented a summary of the MRI safety concerns for 10 categories of devices, and literature-based recommendations derived using Delphi-inspired measures. These recommendations achieved 100% agreement from a panel of 10 radiologists and are meant to serve as practical guidelines for risk assessment.

---

## Acknowledgments

The authors would like to acknowledge and thank the following for their help regarding several topics within this manuscript: Deanna Reynolds MRT (R) (MR); Shelley Landers MRT (R) (MR); Stacy Vilu MRT (R) (MR); Susan Crisp R.T. (NM) (MR); Aimee KM Chan MSc; Alain Berthiaume R.T. (R) (MR); and Joshua Morel R.T. (R) (MR) (MRSC™). [Correction added on October 4, 2019, after first online publication: The Acknowledgments were added.]

## References

- OECD (2019). Magnetic resonance imaging (MRI) exams (indicator). <https://doi.org/10.1787/1d89353f-en>
- Shellock FG, Crues JV. MR procedures: Biologic effects, safety, and patient care. *Radiology* 2004;232:635–652.
- Shellock FG. Magnetic resonance safety update 2002: Implants and devices. *J Magn Reson Imaging* 2002;16:485–496.
- Nyenhuis JA, Park S-M, Kamondetdacha R, Amjad A, Shellock FG, Rezai AR. MRI and implanted medical devices: Basic interactions with an emphasis on heating. *IEEE Trans Device Mater Reliab* 2005;5:467–480.
- Kanal E, Barkovich AJ, Bell C, et al. ACR guidance document on MR safe practices: 2013. *J Magn Reson Imaging* 2013;37:501–530.
- Miller W, Noseworthy MD, Seely J, et al. CAR standard for magnetic resonance imaging. Available at: <https://car.ca/wp-content/uploads/Magnetic-Resonance-Imaging-2011.pdf>
- Union TEPatCotE. Directive 2013/35/EU of the European Parliament and of the Council of 26 June 2013 on the minimum health and safety requirements regarding the exposure of workers to the risks arising from physical agents (electromagnetic fields) (20th individual Directive within the meaning of Article 16(1) of Directive 89/391/EEC) and repealing Directive 2004/40/EC. *Official Journal of the European Union* 2013. p 1–21.
- Indik JH, Gimbel JR, Abe H, et al. 2017 HRS expert consensus statement on magnetic resonance imaging and radiation exposure in patients with cardiovascular implantable electronic devices. *Heart Rhythm* 2017;14:e97–e153.
- Anghelescu DL, Faughnan LG, Baker JN, Yang J, Kane JR. Use of epidural and peripheral nerve blocks at the end of life in children and young adults with cancer: The collaboration between a pain service and a palliative care service. *Paediatr Anaesth* 2010;20:1070–1077.
- Toledano RD, Tsen LC. Epidural catheter design: History, innovations, and clinical implications. *Anesthesiology* 2014;121:9–17.
- Shellock FG. Biomedical implants and devices: Assessment of magnetic field interactions with a 3.0-Tesla MR system. *J Magn Reson Imaging* 2002;16:721–732.
- Owens S, Erturk MA, Ouanes JP, Murphy JD, Wu CL, Bottomley PA. Evaluation of epidural and peripheral nerve catheter heating during magnetic resonance imaging. *Reg Anesth Pain Med* 2014;39:534–539.
- Staats PS, Stinson MS, Lee RR. Lumbar stenosis complicating retained epidural catheter tip. *Anesthesiology* 1995;83:1115–1118.
- Blanchard N, Clabeau JJ, Ossart M, Dekens J, Legars D, Tchaoussoff J. Radicular pain due to a retained fragment of epidural catheter. *Anesthesiology* 1997;87:1567–1569.
- Popping DM, Zahn PK, Van Aken HK, Dasch B, Boche R, Pogatzki-Zahn EM. Effectiveness and safety of postoperative pain management: A survey of 18 925 consecutive patients between 1998 and 2006 (2nd revision): A database analysis of prospectively raised data. *Br J Anaesth* 2008;101:832–840.
- Shellock FG. *Reference manual for magnetic resonance safety, implants, and devices*: 2019 ed.: Los Angeles, California: Biomedical Research Publishing Group; 2019.
- Shellock FG, Audet-Griffin AJ. Evaluation of magnetic resonance imaging issues for a wirelessly powered lead used for epidural, spinal cord stimulation. *Neuromodulation* 2014;17:334–339.
- Mutter UM, Bellut D, Porchet F, Schuknecht B. Spinal magnetic resonance imaging with reduced specific absorption rate in patients harbouring a spinal cord stimulation device — A single-centre prospective study analysing safety, tolerability and image quality. *Acta Neurochir* 2013;155:2327–2332.
- De Andres J, Valia JC, Cerda-Olmedo G, et al. Magnetic resonance imaging in patients with spinal neurostimulation systems. *Anesthesiology* 2007;106:779–786.
- Shellock FG, Zare A, Ilfeld BM, Chae J, Strother RB. In vitro magnetic resonance imaging evaluation of fragmented, open-coil, percutaneous peripheral nerve stimulation leads. *Neuromodulation* 2018;21:276–283.
- Shellock FG, Begnaud J, Inman DM. Vagus nerve stimulation therapy system: in vitro evaluation of magnetic resonance imaging-related heating and function at 1.5 and 3 Tesla. *Neuromodulation* 2006;9:204–213.
- de Jonge JC, Melis GI, Gebbink TA, de Kort GA, Leijten FS. Safety of a dedicated brain MRI protocol in patients with a vagus nerve stimulator. *Epilepsia* 2014;55:e112–115.
- Gorny KR, Bernstein MA, Watson RE Jr. 3 Tesla MRI of patients with a vagus nerve stimulator: Initial experience using a T/R head coil under controlled conditions. *J Magn Reson Imaging* 2010;31:475–481.
- Elkelini MS, Hassouna MM. Safety of MRI at 1.5Tesla in patients with implanted sacral nerve neurostimulator. *Eur Urol* 2006;50:311–316.
- Guzman-Negron JM, Pizarro-Berdichevsky J, Gill BC, Goldman HB. Can lumbosacral magnetic resonance imaging be performed safely in patients with a sacral neuromodulation device? An in vivo prospective study. *J Urol* 2018;200:1088–1092.
- Todt I, Tittel A, Ernst A, Mittmann P, Mutze S. Pain free 3 T MRI scans in cochlear implantees. *Otol Neurotol* 2017;38:e401–e404.
- Majdani O, Leinung M, Rau T, et al. Demagnetization of cochlear implants and temperature changes in 3.0 T MRI environment. *Otolaryngol Head Neck Surg* 2008;139:833–839.
- Kim BG, Kim JW, Park JJ, Kim SH, Kim HN, Choi JY. Adverse events and discomfort during magnetic resonance imaging in cochlear implant recipients. *JAMA Otolaryngol Head Neck Surg* 2015;141:45–52.
- Walker B, Norton S, Phillips G, Christianson E, Horn D, Ou H. Comparison of MRI in pediatric cochlear implant recipients with and without retained magnet. *Int J Pediatr Otorhinolaryngol* 2018;109:44–49.
- Young NM, Rojas C, Deng J, Burrows D, Ryan M. Magnetic resonance imaging of cochlear implant recipients. *Otol Neurotol* 2016;37:665–671.
- Todt I, Rademacher G, Grupe G, et al. Cochlear implants and 1.5 T MRI scans: The effect of diametrically bipolar magnets and screw fixation on pain. *J Otolaryngol Head Neck Surg* 2018;47:11.
- Vogl TJ. *Differential diagnosis in head and neck imaging*. Stuttgart, Germany: Thieme; 1998.
- Wong K, Kozin ED, Kanumuri VV, et al. Auditory brainstem implants: Recent progress and future perspectives. *Front Neurosci* 2019;13:10.
- Reiter MJ, Schwoppe RB, Kini JA, York GE, Suhr AW. Postoperative imaging of the orbital contents. *Radiographics* 2015;35:221–234.
- Bakshandeh H, Shellock FG, Schatz CJ, Morisoli SM. Metallic clips used for scleral buckling: ex vivo evaluation of ferromagnetism at 1.5 T. *J Magn Reson Imaging* 1993;3:559.
- Albert DW, Olson KR, Parel JM, Hernandez E, Lee W, Quencer R. Magnetic resonance imaging and retinal tacks. *Arch Ophthalmol* 1990;108:320–321.
- Joondeph BC, Peyman GA, Mafee MF, Joondeph HC. Magnetic resonance imaging and retinal tacks. *Arch Ophthalmol* 1987;105:1479–1480.
- da Cruz L, Dorn JD, Humayun MS, et al. Five-year safety and performance results from the Argus II Retinal Prosthesis System Clinical Trial. *Ophthalmology* 2016;123:2248–2254.
- Weiland JD, Faraji B, Greenberg RJ, Humayun MS, Shellock FG. Assessment of MRI issues for the Argus II retinal prosthesis. *Magn Reson Imaging* 2012;30:382–389.
- Bowen PK, Shearier ER, Zhao S, et al. Biodegradable metals for cardiovascular stents: From clinical concerns to recent Zn-alloys. *Adv Healthc Mater* 2016;5:1121–1140.
- Shellock FG, Forder JR. Drug eluting coronary stent: in vitro evaluation of magnet resonance safety at 3 Tesla. *J Cardiovasc Magn Reson* 2005;7:415–419.



42. Levine GN, Gomes AS, Arai AE, et al. Safety of magnetic resonance imaging in patients with cardiovascular devices: An American Heart Association scientific statement from the Committee on Diagnostic and Interventional Cardiac Catheterization, Council on Clinical Cardiology, and the Council on Cardiovascular Radiology and Intervention: Endorsed by the American College of Cardiology Foundation, the North American Society for Cardiac Imaging, and the Society for Cardiovascular Magnetic Resonance. *Circulation* 2007; 116:2878–2891.
43. Baikoussis NG, Apostolakis E, Papakonstantinou NA, Sarantitis I, Dougenis D. Safety of magnetic resonance imaging in patients with implanted cardiac prostheses and metallic cardiovascular electronic devices. *Ann Thorac Surg* 2011;91:2006–2011.
44. Shellock FG, Shellock VJ. Metallic stents: Evaluation of MR imaging safety. *AJR Am J Roentgenol* 1999;173:543–547.
45. Hundley WG, Bluemke DA, Finn JP, et al. ACCF/ACR/AHA/NASCI/SCMR 2010 expert consensus document on cardiovascular magnetic resonance: A report of the American College of Cardiology Foundation Task Force on Expert Consensus Documents. *Circulation* 2010; 121:2462–2508.
46. Hug J, Nagel E, Bornstedt A, Schnackenburg B, Oswald H, Fleck E. Coronary arterial stents: Safety and artifacts during MR imaging. *Radiology* 2000;216:781–787.
47. Syed MA, Carlson K, Murphy M, Ingkanisorn WP, Rhoads KL, Arai AE. Long-term safety of cardiac magnetic resonance imaging performed in the first few days after bare-metal stent implantation. *J Magn Reson Imaging* 2006;24:1056–1061.
48. Gerber TC, Fasseas P, Lennon RJ, et al. Clinical safety of magnetic resonance imaging early after coronary artery stent placement. *J Am Coll Cardiol* 2003;42:1295–1298.
49. Porto I, Selvanayagam J, Ashar V, Neubauer S, Banning AP. Safety of magnetic resonance imaging one to three days after bare metal and drug-eluting stent implantation. *Am J Cardiol* 2005;96:366–368.
50. Patel MR, Albert TS, Kandzari DE, et al. Acute myocardial infarction: Safety of cardiac MR imaging after percutaneous revascularization with stents. *Radiology* 2006;240:674–680.
51. Nazarian S, Reynolds MR, Ryan MP, Wolff SD, Mollenkopf SA, Turakhia MP. Utilization and likelihood of radiologic diagnostic imaging in patients with implantable cardiac defibrillators. *J Magn Reson Imaging* 2016;43:115–127.
52. Cohen JD, Costa HS, Russo RJ. Determining the risks of magnetic resonance imaging at 1.5 Tesla for patients with pacemakers and implantable cardioverter defibrillators. *Am J Cardiol* 2012;110:1631–1636.
53. Higgins JV, Sheldon SH, Watson RE Jr, et al. "Power-on resets" in cardiac implantable electronic devices during magnetic resonance imaging. *Heart Rhythm* 2015;12:540–544.
54. Gold MR, Kanal E, Schwitter J, et al. Preclinical evaluation of implantable cardioverter-defibrillator developed for magnetic resonance imaging use. *Heart Rhythm* 2015;12:631–638.
55. Imrich W, Imrich B, Bartsch C, Stertmann WA, Gufler H, Weiler G. Do we need pacemakers resistant to magnetic resonance imaging? *Europace* 2005;7:353–365.
56. Russo RJ, Costa HS, Silva PD, et al. Assessing the risks associated with MRI in patients with a pacemaker or defibrillator. *N Engl J Med* 2017; 376:755–764.
57. Nazarian S, Hansford R, Rahsepar AA, et al. Safety of magnetic resonance imaging in patients with cardiac devices. *N Engl J Med* 2017; 377:2555–2564.
58. Jensen TS, Chin J, Ashby L, et al. Decision memo for magnetic resonance imaging (MRI) (CAG-00399R4); Centers for Medicare & Medicaid Services (CMS) 2018.
59. Batra AS, Balaji S. Post operative temporary epicardial pacing: When, how and why? *Ann Pediatr Cardiol* 2008;1:120–125.
60. Kanal E. Safety of MR imaging in patients with retained epicardial pacer wires. *AJR Am J Roentgenol* 1998;170:213–214.
61. Hartnell GG, Spence L, Hughes LA, Cohen MC, Saouaf R, Buff B. Safety of MR imaging in patients who have retained metallic materials after cardiac surgery. *AJR Am J Roentgenol* 1997;168:1157–1159.
62. Luechinger R, Duru F, Scheidegger MB, Boesiger P, Candinas R. Force and torque effects of a 1.5-Tesla MRI scanner on cardiac pacemakers and ICDs. *Pacing Clin Electrophysiol* 2001;24:199–205.
63. Pfeil A, Drobnik S, Rzanny R, et al. Compatibility of temporary pacemaker myocardial pacing leads with magnetic resonance imaging: An ex vivo tissue study. *Int J Cardiovasc Imaging* 2012;28:317–326.
64. Langman DA, Goldberg IB, Finn JP, Ennis DB. Pacemaker lead tip heating in abandoned and pacemaker-attached leads at 1.5 Tesla MRI. *J Magn Reson Imaging* 2011;33:426–431.
65. Pulver AF, Puchalski MD, Bradley DJ, et al. Safety and imaging quality of MRI in pediatric and adult congenital heart disease patients with pacemakers. *Pacing Clin Electrophysiol* 2009;32:450–456.
66. Imrich W. Re: Cardiac pacemakers in electric and magnetic fields of 400-kV power lines. *Pacing Clin Electrophysiol* 2013;36:266.
67. Higgins JV, Gard JJ, Sheldon SH, et al. Safety and outcomes of magnetic resonance imaging in patients with abandoned pacemaker and defibrillator leads. *Pacing Clin Electrophysiol* 2014;37:1284–1290.
68. Horwood L, Attili A, Luba F, et al. Magnetic resonance imaging in patients with cardiac implanted electronic devices: Focus on contraindications to magnetic resonance imaging protocols. *Europace* 2017; 19:812–817.
69. Padmanabhan D, Kella DK, Mehta R, et al. Safety of magnetic resonance imaging in patients with legacy pacemakers and defibrillators and abandoned leads. *Heart Rhythm* 2018;15:228–233.
70. Shin EJ, Ko CW, Magno P, et al. Comparative study of endoscopic clips: Duration of attachment at the site of clip application. *Gastrointest Endosc* 2007;66:757–761.
71. Accorsi F, Couto G, Simms EL, Lalonde A, Leswick DA. Endoscopic clip MRI screening: A Canada-wide policy survey. *AJR Am J Roentgenol* 2017;209:130–135.
72. Kurt M, Posul E, Tekelioglu V, Yilmaz B, Korkmaz U, Kizildag B. Are MR compatible hemoclips safe after control of hemostasis? *Endoscopy* 2014;46:E471–E471.
73. Olmez S, Ozaslan E, Avcioglu U. Hemoclip retained for more than 2 years. *Endoscopy* 2012;44(Suppl 2)UCTN:E323–324.
74. Mavrogenis G, Del Natale M. Hemostatic clips and magnetic resonance imaging. Are there any compatibility issues? *Endoscopy* 2013; 45:933.
75. Shellock FG, John V. Crues I. *MRI: Bioeffects, safety and patient management*, 14th ed. Los Angeles, California: Biomedical Research Publishing; 2014.
76. Enns RA, Hookey L, Armstrong D, et al. Clinical practice guidelines for the use of video capsule endoscopy. *Gastroenterology* 2017;152:497–514.
77. Bandorski D, Kurniawan N, Baltes P, et al. Contraindications for video capsule endoscopy. *World J Gastroenterol* 2016;22:9898–9908.
78. Bussmann S, Luechinger R, Froehlich JM, et al. Safety of intrauterine devices in MRI. *PLoS One* 2018;13:e0204220.
79. Neumann W, Uhrig T, Malzacher M, Kossmann V, Schad LR, Zoellner FG. Risk assessment of copper-containing contraceptives: The impact for women with implanted intrauterine devices during clinical MRI and CT examinations. *Eur Radiol* 2018 [Epub ahead of print].
80. Ziemann M, Kanal E. Copper T 380A IUD and magnetic resonance imaging. *Contraception* 2007;75:93–95.
81. Nadgir A, Beere D, Barker K. Intrauterine fragmentation of Gyne T380: An uncommon complication. *BMJ Sex Reprod Health* 2004;30: 175–176.
82. Shellock FG. New metallic implant used for permanent contraception in women: Evaluation of MR safety. *Am J Roentgenol* 2002;178:1513–1516.
83. Eshed I, Kushnir T, Shabshin N, Konen E. Is magnetic resonance imaging safe for patients with retained metal fragments from combat and terrorist attacks? *Acta Radiol* 2010;51:170–174.

84. Diallo I, Auffret M, Attar L, Bouvard E, Rousset J, Ben Salem D. Magnetic field interactions of military and law enforcement bullets at 1.5 and 3 Tesla. *Mil Med* 2016;181:710–713.
85. Teitelbaum GP, Yee CA, Van Horn DD, Kim HS, Colletti PM. Metallic ballistic fragments: MR imaging safety and artifacts. *Radiology* 1990; 175:855–859.
86. Eggert S, Kubik-Huch RA, Lory M, et al. The influence of 1.5 and 3 T magnetic resonance unit magnetic fields on the movement of steel-jacketed projectiles in ordnance gelatin. *Forensic Sci Med Pathol* 2015;11:544–551.
87. Karacozoff AM, Pekmezci M, Shellock FG. Armor-piercing bullet: 3-T MRI findings and identification by a ferromagnetic detection system. *Mil Med* 2013;178:e380–385.
88. Dedini RD, Karacozoff AM, Shellock FG, Xu D, McClellan RT, Pekmezci M. MRI issues for ballistic objects: Information obtained at 1.5-, 3- and 7-Tesla. *Spine J* 2013;13:815–822.
89. Smith AS, Hurst GC, Duerk JL, Diaz PJ. MR of ballistic materials: Imaging artifacts and potential hazards. *AJNR Am J Neuroradiol* 1991;12: 567–572.
90. Hess U, Harms J, Schneider A, Schlee M, Ganter C, Hannig C. Assessment of gunshot bullet injuries with the use of magnetic resonance imaging. *J Trauma* 2000;49:704–709.
91. Smugar SS, Schweitzer ME, Hume E. MRI in patients with intraspinal bullets. *J Magn Reson Imaging* 1999;9:151–153.
92. Slavin J, Beaty N, Raghavan P, Sansur C, Aarabi B. Magnetic resonance imaging to evaluate cervical spinal cord injury from gunshot wounds from handguns. *World Neurosurg* 2015;84:1916–1922.
93. Eggert S, Kubik-Huch RA, Klarhofer M, et al. Fairly direct hit! Advances in imaging of shotgun projectiles in MRI. *Eur Radiol* 2015; 25:2745–2753.
94. Shellock FG, Karacozoff AM. Detection of implants and other objects using a ferromagnetic detection system: Implications for patient screening before MRI. *AJR Am J Roentgenol* 2013;201: 720–725.
95. Williamson MR, Espinosa MC, Boutin RD, Orrison WW Jr, Hart BL, Kelsey CA. Metallic foreign bodies in the orbits of patients undergoing MR imaging: Prevalence and value of radiography and CT before MR. *AJR Am J Roentgenol* 1994;162:981–983.
96. Kelly WM, Paglen PG, Pearson JA, San Diego AG, Soloman MA. Ferromagnetism of intraocular foreign body causes unilateral blindness after MR study. *AJNR Am Neuroradiol* 1986;7:243–245.
97. Lawrence DA, Lipman AT, Gupta SK, Nacey NC. Undetected intraocular metallic foreign body causing hyphema in a patient undergoing MRI: A rare occurrence demonstrating the limitations of pre-MRI safety screening. *Magn Reson Imaging* 2015;33:358–361.
98. Ta CN, Bowman RW. Hyphema caused by a metallic intraocular foreign body during magnetic resonance imaging. *Am J Ophthalmol* 2000;129:533–534.
99. Vote BJ, Simpson AJ. X-ray turns a blind eye to ferrous metal. *Clin Exp Ophthalmol* 2001;29:262–264.
100. Platt AS, Wajda BG, Ingram AD, Wei XC, Ells AL. Metallic intraocular foreign body as detected by magnetic resonance imaging without complications — A case report. *Am J Ophthalmol Case Rep* 2017;7: 76–79.
101. Zhang Y, Cheng J, Bai J, et al. Tiny ferromagnetic intraocular foreign bodies detected by magnetic resonance imaging: A report of two cases. *J Magn Reson Imaging* 2009;29:704–707.
102. Murphy M, Black N, Lamping D, et al. Consensus development methods, and their use in clinical guideline development. *Health Technol Assess* 1998;2:i–88.