

available at www.sciencedirect.comjournal homepage: www.elsevier.com/locate/burns

Letter to the Editor

Iatrogenic second-degree burn caused by a catheter encased tubular braid of stainless steel during MRI[☆]

Sir,

I present a case of an abdominal contact burn as the result of heating of a percutaneous transluminal coronary angioplasty (PTCA) catheter during magnetic resonance imaging (MRI). The PTCA catheter body was a continuous wire braid but did not form a loop. It is widely accepted that direct electromagnetic induction in looped cables can cause excessive heating, and many severe burns associated with pulse oximetry or electrocardiography leads during MRI have been reported [1,2]. However, burns caused by PTCA catheters induced are rare. This case report describes the course and etiology of this unusual and interesting incident.

Obstructive jaundice developed in a 55-year-old man because of cancer of the gall bladder. He underwent percutaneous transhepatic biliary drainage (PTBD), but the standard biliary drainage tube was too flexible and soft to be inserted it into the biliary duct, and a PTCA catheter was used instead. After PTBD, the patient underwent whole-body MRI at 1.5 T without sedation. Immediately after the start of MRI, the patient complained of thermal pain on the right side of abdominal wall. The MRI examination was stopped immediately, and the patient was found to have sustained superficial dermal burns of the abdomen where it had come in contact with the PTCA catheter (Fig. 1). The PTCA catheter had been taped to the abdominal wall without forming a loop (Fig. 2). The wound margin was well circumscribed, and a blister had formed, but there was no sign of friction, contusion, or laceration in this area. Treatment was performed conservatively with the application of impregnated ointment (Eki-zalbe[®]) gauze. The wound healed favorably within 12 days without scarring or pigmentation.

Various thermal injuries resulting from MRI have been reported; in particular, many burn incidents associated with physiological monitoring devices, such as electrocardiogram and pulse oximetry leads, are have been reported to the U.S. Food and Drug Administration or described in journals [2–4]. However, burns associated with cardiovascular catheters during MRI are rare. Cardiovascular catheters are often used

to measure intravascular pressures, intracardiac pressures, and cardiac output in severely ill patients, and patients with cardiovascular catheters may require examination with MRI. Shellock et al. evaluated the heating of various cardiovascular catheters associated with MRI and found only a minor temperature increase of 0.2 °C, which they concluded would not pose a risk to a patient undergoing MRI [5]. However, they also cautioned that further safety considerations should be given to cardiovascular devices that have a conductive wire component [5]. In fact, there is one report of a Swan-Ganz catheter including a conductive wire which melted during MRI [5]. In the present case, the PTCA catheter was constructed of two polymer layers, and the outer tube encased a tubular braid of conductive stainless steel (Fig. 3).

Dempsey et al. reviewed numerous reported burns sustained during MRI and addressed the underlying heating mechanisms possibly causing these events [1,2].

One possible mechanism is electromagnetic induction heating. However, the temperature elevation of electromag-

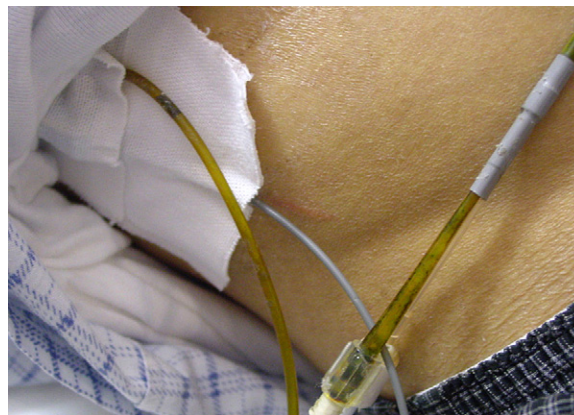


Fig. 1 – The patient had sustained superficial dermal burn on the abdomen where it had come in contact with the PTCA catheter.

[☆] This study was previously presented at the third Kyushu district meeting of Japan pressure ulcer Congress, May 27, 2006 in Sasebo, Japan.

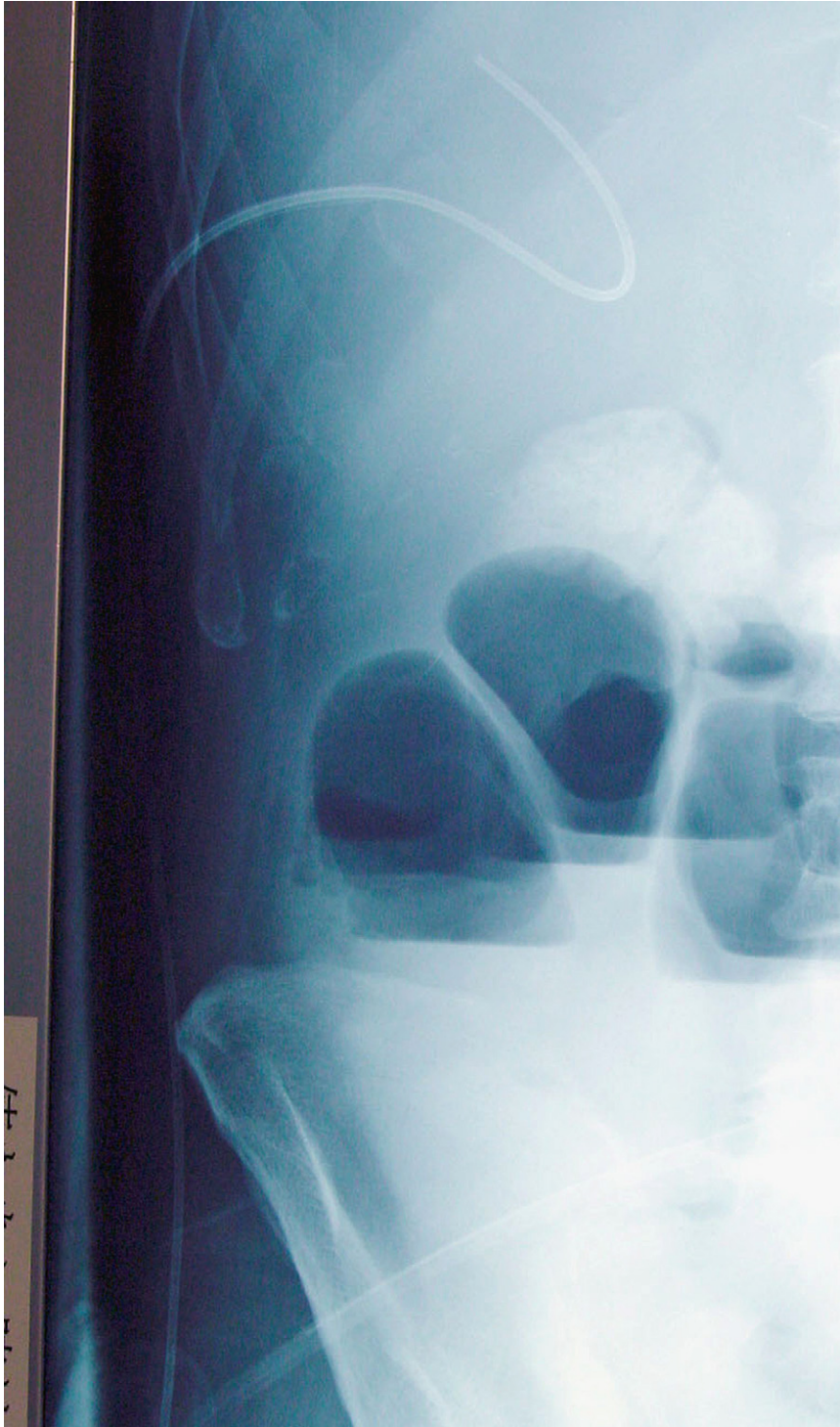


Fig. 2 – A abdominal X-ray film revealed that the PTCA catheter was taped to the abdominal wall without forming a loop.

netic induction is not great (less than 1 °C) and will not result in thermal injury. However, loop formation will induce large currents, which may result in greater heating of the conductive cables [6]. A second possible mechanism is heating in a resonant circuit. Significant temperature increases (more than 60 °C) occur when the conductive circuit is in a resonant condition. A third possible mechanism

is heating due to the antenna effect, in which lengths of cable can serve as a radiofrequency wire antenna in a magnetic resonance condition and the antenna captures electromagnetic waves to extract power. The resonant antenna produces currents, which induce heat and thermal injury.

In our case, the conductive catheter did not form a loop, but the patient sustained superficial dermal burn. I believe

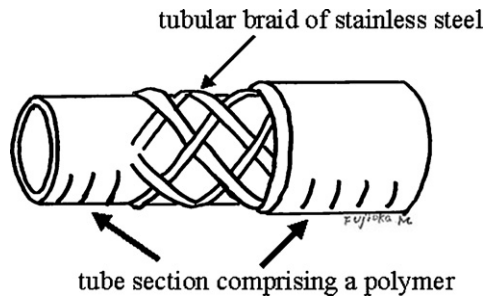


Fig. 3 – Structure of PTCA catheter, with the outer tube section comprising a polymer-encased tubular braid of stainless steel.

that the mechanism of this incident was heating of the conductive catheter owing to the antenna effect. Dempsey et al. have shown in their experiments that the greatest temperature increase associated with the antenna effect was 63.5 °C [1]. Fortunately, the catheter-induced burn in our patient was not severe and required only conservative treatment, because the patient did not receive any sedative that might have prevented him from reporting the pain, and the MRI evaluation could be stopped immediately. If the patient's consciousness had not been clear, the burn injury might have been more severe.

Although a PTCA catheter had been inappropriately used as a substitute for a standard biliary drainage tube in this case, this incident suggest that patients with catheters containing conductive wires can be injured during MRI.

Disclosure

No author of this manuscript received funding, grants, or in-kind support of the research for the preparation of the manuscript. And no author of this manuscript has any association or financial involvement with any organization or commercial entity having a financial interest in or financial conflict with the subject matter or research presented in the manuscript.

REFERENCES

- [1] Dempsey MF, Condon B, Hadley DM. Investigation of the factors responsible for burns during MRI. *J Magn Reson Imag* 2001;13(April (4)):627–31.
- [2] Dempsey MF, Condon B. Thermal injuries associated with MRI. *Clin Radiol* 2001;56(June (6)):457–65.
- [3] Bashein G, Syrory G. Burns associated with pulse oximetry during magnetic resonance imaging. *Anesthesiology* 1991;75(August (2)):382–3.
- [4] Keens SJ, Laurence AS. Burns caused by ECG monitoring during MRI imaging. *Anaesthesia* 1996;51(December (12)):1188–9.
- [5] Shellock FG, Shellock VJ. Cardiovascular catheters and accessories: ex vivo testing of ferromagnetism, heating, and artifacts associated with MRI. *J Magn Reson Imag* 1998;8(November–December (6)):1338–42.
- [6] Nakamura T, Fukuda K, Hayakawa K, Aoki I, Matsumoto K, Sekine T, et al. Mechanism of burn injury during magnetic resonance imaging (MRI)—simple loops can induce heat injury. *Front Med Biol Eng* 2001;11(2):117–29.

Fujioka Masaki*

Department of Plastic and Reconstructive Surgery,
National Nagasaki Medical Center,
1001-1 Kubara 2 Ohmura city,
Zip 856-8562, Japan

Yoshida Shuhei

Kitamura Riko

Department of Plastic and Reconstructive Surgery,
National Nagasaki Medical Center, Nagasaki, Japan

Matsuoka Yohjiro

Chief of the Department of Radiology,
National Nagasaki Medical Center, Nagasaki, Japan

*Corresponding author.

Tel.: +81 957 52 3121; fax: +81 957 54 0292

E-mail address: mfujioka@nmc.hosp.go.jp
(F. Masaki)

0305-4179/\$32.00

© 2007 Elsevier Ltd and ISBI. All rights reserved.
10.1016/j.burns.2007.04.004