

Gadolinium-Associated Nephrogenic Systemic Fibrosis in a 9-Year-Old Boy

Clare Foss, M.D.,* Jeff K. Smith, M.D.,† Luis Ortiz, M.D.,‡ Coral Hanevold, M.D.,‡
and Loretta Davis, M.D.†

*East Virginia Medical School, Norfolk, Virginia, †Medical College of Georgia – Dermatology, Augusta, Georgia,
‡Medical College of Georgia – Pediatrics, Augusta, Georgia

Abstract: We describe a 9-year-old boy on chronic hemodialysis who presented with hyperpigmented, tightly bound-down, indurated plaques of his bilateral lower extremities. Pertinent history included a recent series of magnetic resonance imaging tests utilizing gadolinium-based contrast media. Histopathology showed widened septae with increased fibroblasts and collagen in the subcutis consistent with nephrogenic systemic fibrosis. Nephrogenic systemic fibrosis is a unique fibrosing disorder characterized by skin thickening of the extremities and trunk, resembling that seen in systemic sclerosis. The majority of cases have been reported in dialysis or renal transplant patients. This case of nephrogenic systemic fibrosis in a young child is presented to raise awareness in the pediatric community of nephrogenic systemic fibrosis and of gadolinium contrast being a possible trigger.

Nephrogenic systemic fibrosis (NSF) is a rare, but increasingly appreciated disorder seen in patients with renal dysfunction. Nephrogenic systemic fibrosis is characterized by thickening and hardening of the skin with fibrotic plaques and papules and brawny hyperpigmentation in addition to possible extracutaneous manifestations (1–4). In this report, a young boy developed NFS within months of undergoing magnetic resonance imaging (MRI) tests, which utilized gadolinium-based contrast media.

CASE REPORT

A 9-year-old boy was referred for dermatologic evaluation of a congenital agminated nevus prior to anticipated renal transplantation. He was born prematurely at

27 weeks, and at the age of 4 was diagnosed with acute lymphocytic leukemia. His chemotherapeutic regimen included vincristine, prednisone, doxorubicin, methotrexate, and 6-mercaptopurine. Tumor lysis syndrome during the induction phase caused acute renal failure. He underwent continuous cycling peritoneal dialysis, then hemodialysis, with progression to chronic renal failure. Episodes of pancreatitis, adult respiratory distress syndrome, and sepsis necessitated placement of multiple central venous access lines, predisposing him to major vessel thromboses. Because of growth retardation, daily growth hormone was prescribed. Three months prior to presentation, in preparation for renal transplantation, a MRI test utilizing 0.1 mmol/kg gadodiamide, a gadolinium-based contrast agent, was performed to evaluate the abdominal and pelvic vasculature. Because of

Address correspondence to Clare Foss, Eastern Virginia Medical University, 114 E Severn Rd, Norfolk, VA 23505, or e-mail: clare.foss@gmail.com.

inconclusive results, 3 months later, a repeat MRI test was performed utilizing 0.3 mmol/kg gadodiamide.

Two months following this procedure, the mother noticed skin changes on the child's legs. At routine dermatologic follow-up, hyperpigmented, shiny, tightly bound-down plaques of the lower extremities were noted. This fibrotic process involved primarily the lateral and posterior calves and to a lesser extent the anterior and lateral thighs (Fig. 1). A joint examination demonstrated no loss of mobility or function. A punch biopsy of skin showed widened septae with increased fibroblasts and collagen in the subcutis characteristic of NSF (Fig. 2). The growth hormone was discontinued. Treatment with calcipotriene ointment under compression stocking occlusion was recommended and weekly physical therapy was initiated. At the 4-month follow-up, the patient demonstrated full joint mobility, and the cutaneous examination was unchanged. Further gadolinium-based imaging is to be avoided in this patient.

DISCUSSION

Nephrogenic systemic fibrosis is a relatively rare, recently described entity which affects patients with renal dys-

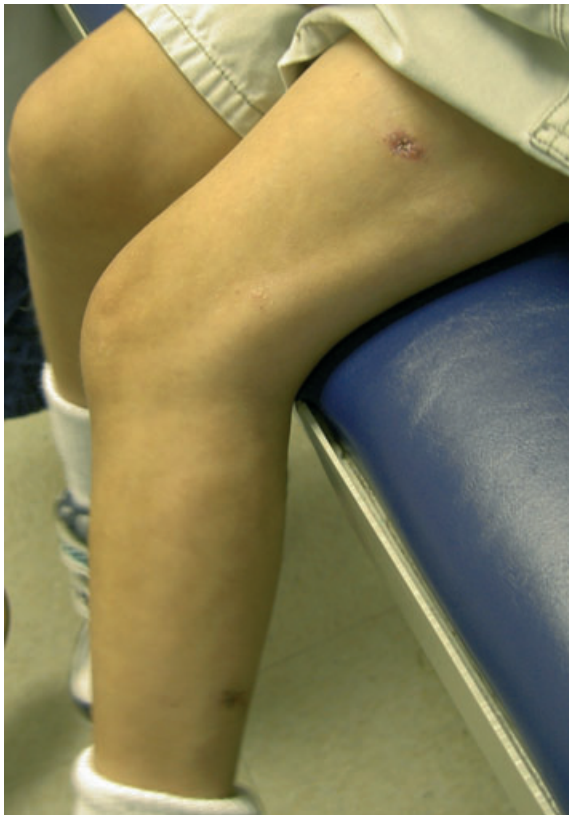

Figure 1. Hyperpigmented, shiny, tightly bound-down plaques of the lower extremities.

function. In 2001 Cowper et al first detailed the clinical and pathological findings of this condition which was coined nephrogenic fibrosing dermopathy (NFD) (1). When evidence emerged that this pathologic process affected more than just the skin, the name was changed to NSF (2,3).

Characteristic clinical findings of NSF include thickening and hardening of the skin with fibrotic plaques and papules and brawny hyperpigmentation. The trunk and extremities are most commonly involved, while the face is usually spared (4). Affected skin may be painful or pruritic. Contractures of involved joints may develop and can be debilitating. Some patients demonstrate involvement of the heart, lungs, diaphragm, skeletal muscles or kidneys which can be fatal. On histopathologic examination, skin lesions show proliferation of dermal spindle cells, thick collagen bundles with surrounding clefts, and variable amounts of mucin and elastic fibers (5).

As a newly recognized disease, the etiology and pathogenesis of NSF have been debated. Recent observations, however, strongly suggest the administration of gadolinium-based contrast media may be a trigger for the onset of NSF. Grobner reported that five of nine patients with end stage renal disease who had received gadolinium-based contrast media for magnetic resonance angiography (MRA) developed NSF. The onset of skin findings occurred 2–4 weeks after the MRA. The affected patients were found to have had a metabolic acidosis at the time of the gadolinium contrast administration while unaffected patients did not (6). Marckmann et al reviewed 13 confirmed cases of NSF and found that all patients had been exposed to gadolinium-based contrast prior to the development of their symptoms. No other event

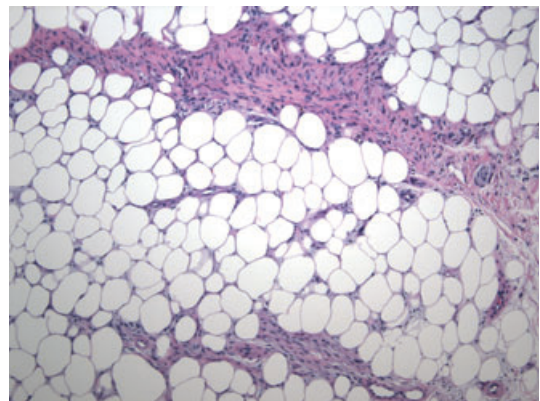


Figure 2. A punch biopsy of subcutis with widened septae containing an increased number of fibroblasts and increased collagen, characteristic of nephrogenic systemic fibrosis (40 \times).

or exposure was found in common with more than a minority of the patients. The time from exposure until the first signs of the disease ranged from 2 to 75 days. None of those patients were found to have had metabolic acidosis (7).

The discovery of gadolinium deposition in the tissue of some patients with NSF further supports an association between exposure to this contrast media and the disease (8,9). High et al reported detection of gadolinium in 4 of 13 tissue specimens from seven patients with NSF using a field emission scanning electron microscope with energy dispersive spectroscopy. In one of the samples, gadolinium particles were found in the papillary dermis underlying an actinic keratosis. In the other three gadolinium-containing tissues, the metal was present in areas of fibrosis. The authors hypothesized that macrophages phagocytize retained gadolinium as the metal particles were associated with cell bodies and appeared to be intracellular, possibly contained within lysosomes. The authors' speculation as to why gadolinium was not detected in all specimens included possible limitation of their technique, length of time since exposure, dose and brand of contrast media, and the efficacy of dialysis after exposure (8). Using a similar technique in another case of NSF, Boyd et al detected gadolinium in association with areas of calcium phosphate deposition in blood vessels (9).

Multiple hypotheses have emerged in the literature regarding the mechanism by which gadolinium may cause development of NSF. When used clinically, gadolinium is in chelate form, as free gadolinium is a toxic substance. Administration of high doses of gadolinium may be a relevant risk factor for patients with renal impairment. Many of the reported cases occurred after MRA (which requires two to three times the dose 0.2–0.3 mmol/kg compared with 0.1 mmol/kg with conventional MRI) (10).

Mobilization of iron is one possible link between gadolinium and NSF. Metals such as iron can cause transmetallation, a reaction which releases free gadolinium from its chelate (11). Large deposits of iron as well as other metals have been identified in NSF tissue specimens (8). Release of iron from stores after exposure to gadolinium may cause oxidative stress, inflammation and tissue injury by free gadolinium and catalytic iron (11).

The activation of tissue transglutaminases by gadolinium has also been highlighted as a possible mechanism of the disease. These enzymes which are involved in wound healing and fibrosis have been shown by immunohistochemical staining to have increased expression and activation in tissues of NSF (12).

The vast majority of cases reported on the NFD registry have been adult patients (13). There have been few published pediatric cases of NSF, and until recently none had cited exposure to gadolinium-based contrast media (13–16). In a letter, Dharnidharka et al reviewed the records of two previously published cases of children with NSF, and found that in both cases gadolinium exposure had occurred prior to the onset of the disease (17). We present this case of NSF occurring in a young child after exposure to gadolinium contrast in order to raise awareness in the pediatric community of this possible trigger.

REFERENCES

1. Cowper SE, Su LD, Bhawan J et al. Nephrogenic fibrosing dermopathy. *Am J Dermatopathol* 2001;23:383–393.
2. Ting WW, Stone MS, Madison KC et al. Nephrogenic fibrosing dermopathy with systemic involvement. *Arch Dermatol* 2003;139:903–906.
3. Kucher C, Steere J, Elenitsas R et al. Nephrogenic fibrosing dermopathy/nephrogenic systemic fibrosis with diaphragmatic involvement in a patient with respiratory failure. *J Am Acad Dermatol* 2006;54:S31–S34.
4. Streams BN, Liu V, Liegeois N et al. Clinical and pathologic features of nephrogenic fibrosing dermopathy: a report of two cases. *J Am Acad Dermatol* 2003;48:42–47.
5. Galan A, Cowper SE, Bucala R. Nephrogenic systemic fibrosis (nephrogenic fibrosing dermopathy). *Curr Opin Rheumatol* 2006;18:614–617.
6. Grobner T. Gadolinium — a specific trigger for the development of nephrogenic fibrosing dermopathy and nephrogenic systemic fibrosis? *Nephrol Dial Transplant* 2006;21:1104–1108.
7. Marckmann P, Skov L, Rossen K et al. Nephrogenic systemic fibrosis: suspected causative role of gadodiamide used for contrast-enhanced magnetic resonance imaging. *J Am Soc Nephrol* 2006;17:2359–2362.
8. High WA, Ayers RA, Chandler J et al. Gadolinium is detectable within the tissue of patients with nephrogenic systemic fibrosis. *J Am Acad Dermatol* 2007;56:21–26.
9. Boyd AS, Zic JA, Abraham JL. Gadolinium deposition in nephrogenic fibrosing dermopathy. *J Am Acad Dermatol* 2007;56:27–30.
10. Grobner T, Prischl FC. Gadolinium and nephrogenic systemic fibrosis. *Kidney Int* 2007;72:260–264.
11. Swaminathan S, Horn TD, Pellowski D et al. Nephrogenic systemic fibrosis, gadolinium and iron mobilization. *N Engl J Med* 2007;357:720–722.
12. Parsons AC, Yosipovitch G, Sheehan DJ et al. Transglutaminases: the missing link in nephrogenic systemic fibrosis. *Am J Dermatopathol* 2007;29:433–436.
13. Auron A, Shao L, Warady BA. Nephrogenic fibrosing dermopathy in children. *Pediatr Nephrol* 2006;21:1307–1311.
14. Jan F, Segal JM, Dyer J et al. Nephrogenic fibrosing dermopathy: two pediatric cases. *J Pediatr* 2003;143:678–681.

15. Jain SM, Wesson S, Hassanein A et al. Nephrogenic fibrosing dermopathy in pediatric patients. *Pediatr Nephrol* 2004;19:467–470.
16. DiCarlo JB, Gupta EA, Solomon AR. A pediatric case of nephrogenic fibrosing dermopathy: improvement after combination therapy. *J Am Acad Dermatol* 2006;54:914–916.
17. Dharnidharka VR, Wesson SK, Fennell RS. Gadolinium and nephrogenic fibrosing dermopathy in pediatric patients. *Pediatr Nephrol* 2007;22:1395.