

syngo TWIST for Dynamic Time-Resolved MR Angiography

TWIST (Time-resolved Angiography With Interleaved Stochastic Trajectories)

Gerhard Laub, Ph.D.; Randall Kroeker, Ph.D.

Siemens Medical Solutions at University of California in Los Angeles, CA, USA

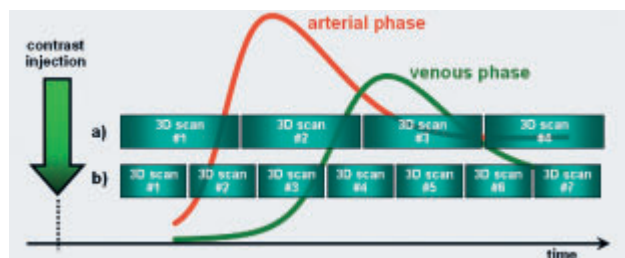
Introduction

Siemens, a leader in advanced engineering as well as applications development, has made 3D dynamic imaging available in the late 90s for the MAGNETOM Vision. The speed of dynamic imaging got an extra boost with the strong 40 mT/m gradients available with the MAGNETOM Sonata. Since then, dynamic imaging has gone through several changes and improvements, including the expansion of parallel imaging with the Tim (Total imaging matrix) technology, and more recently, the new k-space coverage now available with the *syngo* TWIST technique. *syngo* TWIST achieves significant improvements in temporal and spatial resolution and faster tracking of dynamic processes relative to the other versions of dynamic imaging introduced earlier.

syngo TWIST offers a practical, flexible, and elegant way to perform sub-second, time-sequential 3D measurements, both at 1.5T and 3T field strengths. This can be used in combination with contrast injection to provide dynamic clinical information, including the evaluation of abnormal vascular anatomy as well as vascular hemodynamics, and perfusion measurements. Common applications include examining a range of vascular pathologies as well as other dynamic processes such as vocal cord movement, speech forma-

tion/singing, swallowing, and other voluntary and involuntary movements in the body. In this paper we will present the underlying principles for *syngo* TWIST and we will present initial clinical applications related to dynamic, contrast-enhanced MR Angiography (MRA) as shown in Fig. 1. Following the intravenous injection of an MR contrast agent we will acquire a series of fast 3D imaging sequences. The necessary temporal resolution depends on the physiology of the contrast injection, and can be as fast as 1 second, or less, for intracranial structures, up to several seconds for slower processes in the peripheral vasculature.

syngo TWIST is available with software *syngo* MR B13 for all systems with Tim technology, and can be used in combination with an ultra-short TR supported by the gradient performance to achieve a high temporal resolution. *syngo* TWIST is fully compatible with parallel imaging (*syngo* GRAPPA or mSENSE) thus allowing subsecond 3D acquisitions with reasonable spatial resolution. The *syngo* TWIST acceleration can be up to 20 times compared to a standard, full k-space acquisition. Furthermore, *syngo* TWIST is compatible with the Inline angio card to allow fast processing similar to the standard angio sequences.



[Figure 1] Basic idea of contrast-enhanced dynamic MRA. a) Conventional measurements with relatively poor temporal resolution. b) *syngo* TWIST reduces the time between subsequent 3D data sets to better distinguish between the arterial and venous phase.

Methods

To shorten scan time in 3D imaging, one can use any or a combination of the following to achieve time-resolved dynamic imaging:

- Use a short TR
- Apply rectangular field-of-view (FoV)
- Use Partial Fourier
- Reduce spatial resolution
 - In-plane resolution
 - Slice resolution
- Use parallel imaging

To further increase the temporal resolution, one can manipulate the coverage of k-space during data acquisition. For

example, one does not have to cover k-space with a uniform rate at every point. This has been demonstrated many years ago in a MAGNETOM Vision system using a random phase encoding strategy where the low k-space lines are visited more frequently (CURE, MRM 33: 326-336, 1995). We have adopted this basic strategy in a straight forward fashion to a three-dimensional acquisition scheme.

In a first step, k-space is divided into two regions A and B as shown in Fig. 2.

Fig. 2 shows the data points in k-space divided into region A and B. A is the low frequency central region responsible for the overall image contrast. B is the higher frequencies outer k-space region responsible for image details. As is well-known, the number of k-space points depends on the spatial resolution and field-of-view (FOV) in the in-plane and through-plane phase encoding directions. A larger size of region "A" better defines the overall image contrast resolution, whereas a larger size of region "B" improves the spatial resolution in the image.

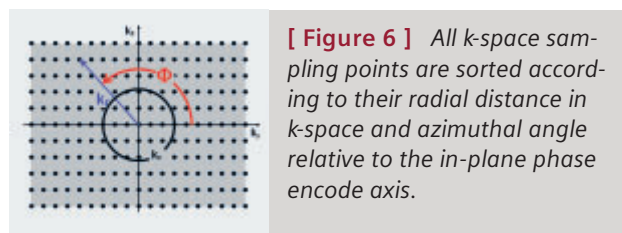
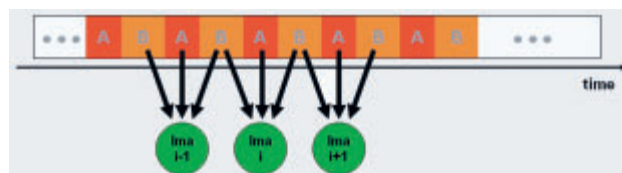
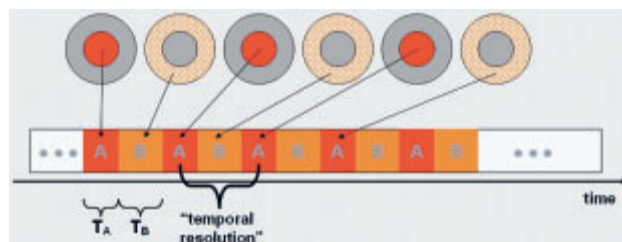
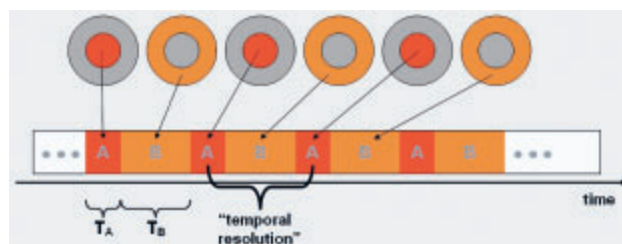
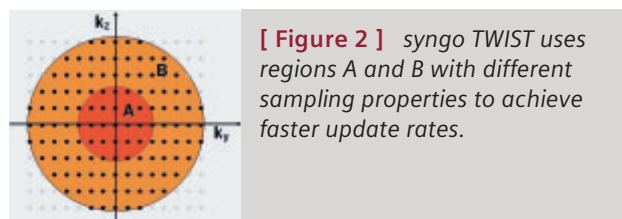
Region A contains a total number of N_A sampling points, and region B contains N_B sampling points. In the conventional scenario, all sampling points in A and B are sampled at a uniform rate as shown in Fig. 3.

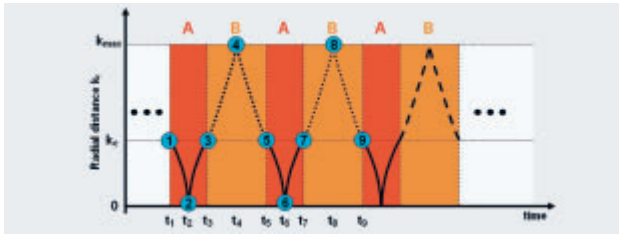
In an effort to shorten the time between two subsequent A-regions the k-space points in the B-region are visited less frequently. This is indicated in Fig. 4 as shaded area in "B".

In Fig. 4, the time intervals between subsequent A regions are shorter than in the conventional approach, i.e., the apparent temporal resolution is increased. However, k-space is not completely scanned in one B interval. To fill in the missing points, data from several B intervals are copied into the raw data to calculate the 3D image data at time point t_i as shown in Fig. 6.

The remaining step in understanding syngo TWIST is to look at the k-space trajectory for regions A and B, respectively. In a first step, all sampling points that are to be measured will be sorted according to their radial distance in k-space, and the azimuthal angle (see Fig. 6).

The details of the syngo TWIST trajectory are shown in Fig. 7. The k-space trajectory in both region A and B is starting and ending at k_c . Specifically, the trajectory starts in region A at point 1 to take every other k-space point of the sorted k-space distribution until the center is reached at point 2. From here every other remaining k-space point is used outwards to point 3. In region B we use a bigger, variable stepping rate until point 3 is reached, and come back to the interface at point 4. Region A will be repeated similar to the first time (point 5 – 7) followed by region B with a different trajectory to fill the missing points of the first B trajectory. The key

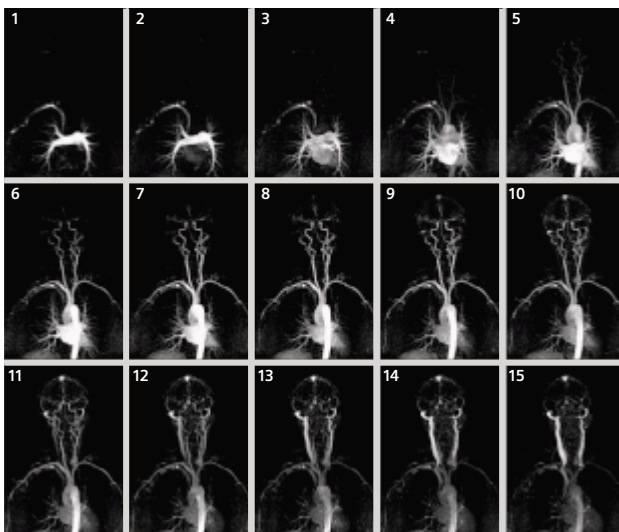




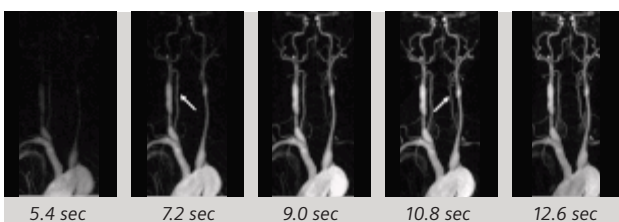
[Figure 7] *k*-space trajectory for syngo TWIST.



[Figure 8] Snapshots of *k*-space filling at time points t_1 through t_9 from Fig. 7.



[Figure 9] Time-resolved contrast-MRA study of the carotid artery in a normal volunteer. The syngo TWIST acceleration factor is 2.1 to provide a temporal resolution of 2 seconds.



[Figure 10] Time-resolved MRA using syngo TWIST in a patient with steal syndrome. Data are acquired on MAGNETOM Trio.

Courtesy of Dr. J. Paul Finn, UCLA, Los Angeles, USA.

advantage of this technique is that a full range of *k*-space coverage from $k=0$ to k_{max} occurs for every repetition of the basic cycle. Thus, high-frequency information is updated at the same rate as the central region A.

To further illustrate the *k*-space sampling strategy of syngo TWIST, we take snapshots of *k*-space filling at the timepoints t_1 through t_9 . These snapshots are shown in Fig. 8.

Overall, *k*-space is acquired in a random fashion even though there is a well-defined strategy behind every sampling point. This behavior explains the name of “stochastic trajectories” as part of the name of syngo TWIST (Time-resolved Angiography With Stochastic Trajectories).

Clinical Applications

There are many benefits of using dynamic syngo TWIST for clinical applications. These include:

- Better detection of vascular diseases such as in arteriovenous malformations (AVM) or shunts by providing the dynamic information.
- Better assessment of vascular diseases such as in peripheral obstructive artery disease (POAD) or steal phenomenon by visualizing the hemodynamics.
- Smaller amounts of contrast agent required for the contrast enhancement study.
- Complete elimination of venous contamination even in abnormal hemodynamic states.

Fig. 9 shows the series of maximum intensity projection (MIP) images of a normal volunteer. This data set was acquired on MAGNETOM Trio using a combination of the Head Matrix coil (12 elements), Neck Matrix coil (4 elements), and one row of the Body Matrix coil (3 elements), and the Spine Matrix coil (3 elements). The protocol uses a FoV of 500 mm with a readout matrix of 512, and a parallel acceleration factor of 3 to enable a spatial resolution of 1.2 mm x 1.0 mm x 4.0 mm. The syngo TWIST parameters are 30% for the size of region A, a 25% for the undersampling in B. Therefore, the syngo TWIST acceleration is 2.1, i.e. the syngo TWIST acquisition provides a 2.1-fold acceleration over a conventional acquisition using similar measurement parameters. Adding the values for parallel imaging and partial Fourier, the total acceleration corresponds to 9.8. In other words, the syngo TWIST acquisition is nearly 10 times faster than a standard, full *k*-space acquisition technique. This measurement is performed with a small amount of contrast agent, sufficient to create enough T1-shortening during the course of data acquisition. This is important for many clinical applications as it provides the visualization of the passage of a contrast bolus, and it also allows to repeat the measurement at several locations. Typically, the time-resolved MRA is fol-

lowed by a high-resolution scan. Due to the small amount of contrast agent necessary for the time-resolved MRA the high-resolution scan is not affected by the contrast which is already in the vascular system.

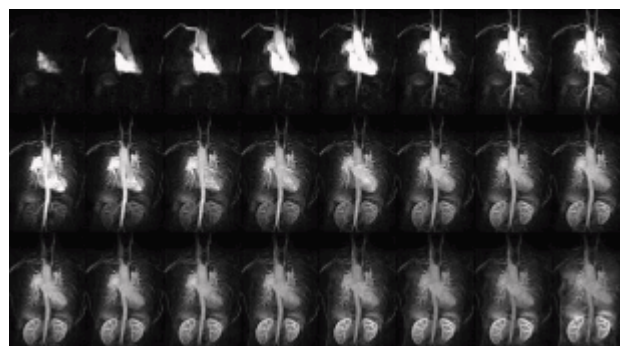
A clinical application of this technique is demonstrated in Fig. 10. The filling of the left vertebral artery is delayed (see arrow) due to a steal syndrome.

syngo TWIST can be applied in all vascular territories. Fig. 11 shows a series of MIPs in a patient with congenital vascular disease. The data were acquired on the MAGNETOM Avanto using two sets of Body Matrix coils, and the corresponding elements of the Spine Matrix coil. A total of 24 coil elements were used to acquire signal over a FoV of 500 mm with a parallel imaging factor of 2 in the left-right direction.

Finally, Fig. 12 shows the potential of *syngo* TWIST as a full 4-dimensional contrast-enhanced MRA technique. In this example we have used the following *syngo* TWIST parameters: size A = 15%, sampling rate B = 20%, providing a TWIST acceleration of 3.125, and a total acceleration of 14.6. The spatial resolution is 1.3 mm x 1.0 mm x 1.3 mm, and the time between individual 3 data sets is 2.5 seconds. In other words, the *syngo* TWIST measurement provided data that would otherwise take 36 seconds to acquire. Due to the short time between subsequent A regions only a small amount of contrast agent is necessary to provide a sufficiently large contrast bolus.

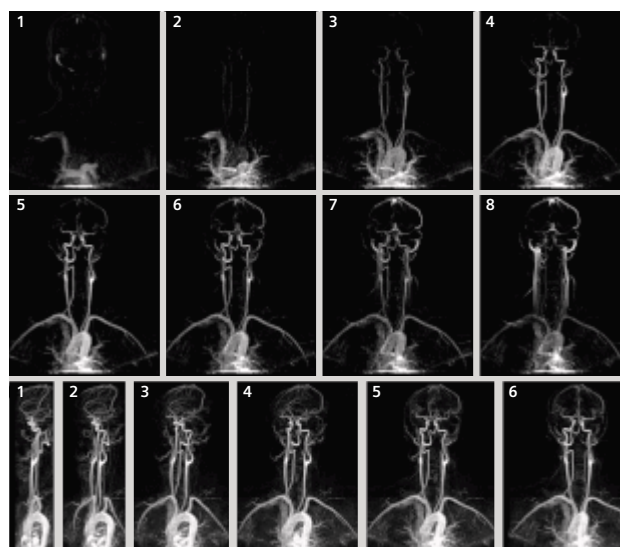
Summary

syngo TWIST is a versatile technique that can be adjusted to all imaging needs of time-resolved contrast-enhanced MRA. *syngo* TWIST is available on all MAGNETOM systems with Tim (Total imaging matrix) technology, and is a very powerful tool in the functional assessment of vascular disease.



[Figure 11] Time-resolved MRA using *syngo* TWIST in a patient with congenital vascular disease. Data are acquired on MAGNETOM Avanto.

Courtesy of Dr. J. Paul Finn, UCLA, Los Angeles, USA.



[Figure 12] Top: Series of coronal MIPs in a 4D MRA study. Bottom: Series of MIPs at different projection angles of the arterial phase of the same 4 measurements.

References

- [1] Hennig J, Scheffler K, Laubenberg J, Strecker R. Time-resolved projection angiography after bolus injection of contrast agent. *Magn Reson Med* 1997; 37: 341–345.
- [2] Finn JP, Baskaran V, Carr JC, et al. Thorax: low-dose contrast-enhanced three-dimensional MR angiography with subsecond temporal resolution: initial results. *Radiology* 2002; 224: 896–904.
- [3] Korosec FR, Frayne R, Grist TM, Mistretta CA. Time-resolved contrast-enhanced 3D MR angiography. *Magn Reson Med* 1996; 36: 345–351.
- [4] Riederer SJ, Bernstein MA, Breen JF, et al. Three-dimensional contrast-enhanced MR angiography with real-time fluoroscopic triggering: design specifications and technical reliability in 330 patient studies. *Radiology* 2000; 215: 584–593.

- [5] Cashen TA, Carr JC, Shin W et al, Intracranial Time-Resolved Contrast-Enhanced MR Angiography at 3T. *American Journal of Neuroradiology* 2006; 27: 822–829.
- [6] Fink C, Puderbach M, Ley S, et al. Time-resolved echo-shared parallel MRA of the lung: observer preference study of image quality in comparison with non-echo-shared sequences. *European Radiology* 2005; 15(10) 2070–2074.
- [7] Pinto C, Hickey R, et al. Time-resolved MR Angiography with Generalized Autocalibrating Partially Parallel Acquisition and Time-resolved Echo-sharing Angiographic Technique for Hemodialysis Arteriovenous Fistulas and Grafts. *Journal of Vascular and Interventional Radiology* 2006; 17: 1003–1009.